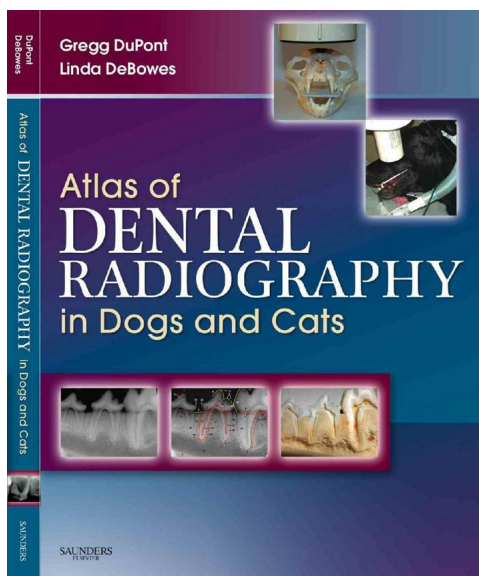


WHY SHOULD YOU DO WHOLE-MOUTH INTRA-ORAL DENTAL RADIOGRAPHS?

The question has been posed, “what are the indications for taking intra-oral dental radiographs?” While some have proposed a lengthy list of indications for radiographing, it really is extremely simple. If you have a live patient with an oral cavity under general anesthesia, you should do whole-mouth intra-oral dental radiographs. There are a few exceptions but by and large, your patients (and their owners) are going to be best served if you take whole mouth radiographs. For one thing, there is a lot of dental pathology out there that will go completely undetected if you are not radiographing. But there is more.

Obtaining diagnostic intra-oral radiographic images is a learned skill. You can only learn a learned skill by doing it - over and over and over. So if you want to get good, consistent results quickly, you need to practice, practice, practice.

Once you have obtained these marvelous images, you need to interpret them accurately. This is also a learned skill. You can learn a fair amount about this by reading this excellent textbook:



There are also many articles on the Old CUSP Articles page at www.toothvet.ca that have lots of radiographs.

The next step is to read a lot of radiographs. There is a wide range of normal and knowing when something is within this range and when you are seeing true pathology gets so much easier after you have read thousands of images.

Another reason for taking whole-mouth intra-oral dental radiographs is to protect your license. Clients are starting to register complaints about shoddy dental care. Have a look at this paper: www.toothvet.ca/PDFfiles/Carrot_Or_Stick.pdf. With more and more clinics embracing dental radiography, it is becoming very hard to defend offering any dental services without radiographs.

Still not convinced? Okay, here is a (partial) list of specific reasons:

- tooth resorption is so common in cats, you should assume every cat has some tooth resorption until proven otherwise (by detailed clinical and radiographic evaluation).

- tooth resorption is becoming very common in dogs as well, so you need to be looking for this as well.

- every apparently missing tooth is either impacted or had retained root(s) until proven otherwise radiographically.

- a lot of teeth that look clinically normal have pulp necrosis and this will be missed without radiographs.

- there are several deformities of root structure that will only be found radiographically.

- every worn, chipped and broken tooth has endodontic disease until proven otherwise and this calls for radiographs.

- some periodontal pockets are hard to probe because the teeth are crowded together but these defects may be detected radiographically.

- our patients cannot tell us if they have a tooth ache, so we have to go looking for pathology.

- you need to document the situation as it is today as a baseline for comparison in the future.

So, if you have a dental xray machine, use it - a lot. If you do not have a dental xray machine, get one. And then use it - a lot!

And here are some references: (next page)

[Am J Vet Res.](#) 1998 Jun;59(6):686-91.

Diagnostic value of full-mouth radiography in dogs.

[Verstraete FJ](#), [Kass PH](#), [Terpak CH](#).

Source

Department of Surgical and Radiological Sciences, School of Veterinary Medicine, University of California, Davis 95616, USA.

Abstract

OBJECTIVE:

To determine the diagnostic value of full-mouth radiography in dogs.

SAMPLE POPULATION:

Prospective series of 226 dogs referred for dental treatment without previous full-mouth radiographic views being available.

PROCEDURE:

In a prospective nested case-control analysis of multiple outcomes in a hospital cohort of dogs presented for dental treatment, full-mouth radiographic views were obtained prior to oral examination and charting. After treatment, clinical and radiographic findings were compared, with reference to presenting problems, main clinical findings, additional information obtained from the radiographs, and unexpected radiographic findings. The importance of the radiographic findings in therapeutic decision-making was assessed.

RESULTS:

The main clinical findings were radiographically confirmed in all dogs. Selected presenting problems and main clinical findings yielded significantly increased odds ratios for a variety of other conditions, either expected or unexpected. Radiographs of teeth without clinical lesions yielded incidental or clinically important findings in 41.7 and 27.8% of dogs, respectively, and were considered of no clinical value in 30.5%. Radiographs of teeth with clinical lesions merely confirmed the findings in 24.3% of dogs, yielded additional or clinically essential information in 50.0 and 22.6%, respectively, and were considered of no value in 3.1%. Older dogs derived more benefit from full-mouth radiography than did younger dogs. Incidental findings were more common in larger dogs.

CLINICAL RELEVANCE:

Diagnostic yield of full-mouth radiography in new canine patients referred for dental treatment is high, and the routine use of such radiographs is justifiable.

[Am J Vet Res.](#) 1998 Jun;59(6):692-5.

Diagnostic value of full-mouth radiography in cats.

[Verstraete FJ](#), [Kass PH](#), [Terpak CH](#).

Source

Department of Surgical and Radiological Sciences, School of Veterinary Medicine, University of California 95616, USA.

Abstract

OBJECTIVE:

To determine the diagnostic value of full-mouth radiography in cats.

SAMPLE POPULATION:

115 cats referred for dental treatment without a previous full-mouth radiographic series available.

PROCEDURE:

In a prospective nested case-control analysis of multiple outcomes in a hospital cohort of cats referred for dental treatment, full-mouth radiography was done prior to oral examination and charting. After treatment, the clinical and radiographic findings were compared, with reference to presenting problems, main clinical findings, additional information obtained from radiography and unexpected radiographic findings. Importance of the radiographic findings in therapeutic decision making was assessed.

RESULTS:

The main clinical findings were radiographically confirmed in all cats. Odontoclastic resorption lesions, missed on clinical examination, were diagnosed in 8.7% of cats. Analysis of selected presenting problems and main clinical findings yielded significantly increased odds ratios for a variety of other conditions, either expected or unexpected. Radiographs of teeth without clinical lesions yielded incidental or clinically important findings in 4.8 and 41.7% of cats, respectively, and were considered of no clinical value in 53.6%. Radiographs of teeth with clinical lesions merely confirmed the findings in 13.9% of cats, but yielded additional or clinically essential information in 53.9 and 32.2%, respectively.

CLINICAL RELEVANCE:

The diagnostic yield of full-mouth radiography in new feline patients referred for dental treatment is high, and routine use of full-mouth radiography is justifiable.

[J Am Anim Hosp Assoc.](#) 2013 Jan-Feb;49(1):23-30. doi: 10.5326/JAAHA-MS-5830. Epub 2012 Nov 12.

Assessment of dental abnormalities by full-mouth radiography in small breed dogs.

[Kim CG](#), [Lee SY](#), [Kim JW](#), [Park HM](#).

Source

Tae-il Animal Medical Center, Seoul, South Korea.

Abstract

This study was performed to evaluate full-mouth radiographic findings to determine the prevalence of dental abnormalities and analyze the relationship between dental abnormalities and age in small breed dogs. Sixteen predetermined categories of abnormal radiographic findings were evaluated in 233 small breed dogs. In total, 9,786 possible permanent teeth could be evaluated. Of those, 8,308 teeth were evaluated and abnormal radiographic findings were found in 2,458 teeth (29.6%). The most common teeth with abnormal radiographic findings were the mandibular first molars (74.5% on the left and 63.9% on the right) and the maxillary fourth premolars (40.5% on the left and 38.2% on the right). Bone loss of any type (15.8%) was the most commonly detected radiographic abnormal finding among the 16 categories. Dental conditions with a genetic predisposition were frequently occurred in the mandibular premolar teeth. Shih tzu frequently had unerupted teeth and dentigerous cysts. Among the teeth with abnormal radiographic findings, 4.5%, 19.8%, and 5.3% were considered incidental, additional, and important, respectively. Findings that were only detected on radiographs, which were not noted on routine oral examination, were more common in older dogs. Full-mouth radiographic evaluation should be performed to obtain important information for making accurate diagnoses.