

The Tooth

The tooth is the basic unit of concern in dentistry. Therefore, any study of dentistry must start with an understanding of the anatomy and physiology of the tooth. In veterinary dentistry, there is a wide range of tooth types and morphologies, but this discussion will focus on a simple, single rooted tooth as might be found in humans, dogs and cats.

Each tooth has a *crown* (the portion above the normal gingival margin) and a *root* (the portion below the normal gingival margin). The bulk of the tooth is composed of *dentin*. The dentin of the crown is covered by *enamel* and the dentin of the root is covered by *cementum*. The cemento-enamel junction marks the transition from root to crown and is known as the *cervix* or *cervical region*. Inside the dentin of the root and the crown is a hollow chamber filled with the soft tissue known as *pulp*.

Enamel is the hardest tissue in the mammalian body. It is composed of crystals of hydroxyapatite arranged in prisms roughly perpendicular to the junction with the underlying dentin. The closely packed crystals occupy 88% of the volume of the enamel, the remaining 12% being water and organic material. By weight, enamel is 96% mineral. It is acellular and considered non-living.

Enamel is formed by ameloblasts during tooth development. Amelogenesis stops prior to tooth eruption and no more enamel is produced. Once the tooth has erupted into the oral cavity, enamel is lost gradually (or rapidly if the animal has a chewing vice) to chemical and mechanical forces.

Anything that disrupts the delicate ameloblasts during enamel production will result in defective enamel which may be very weak and brittle. This defective enamel will be present at eruption but will soon be lost to abrasive forces. This leaves an area of exposed dentin and rough margins to the surrounding enamel. *Enamel hypoplasia*, as it is commonly known, may affect a single tooth if the insult is localized (e.g., infection from a fractured deciduous tooth, iatrogenic from careless deciduous tooth extraction, bruising from local facial trauma). Many systemic conditions, such as pyrexia, hypoproteinemia, epitheliotrophic virus infection can cause widespread enamel hypoplasia on all teeth that are developing during the time of the illness. [A serious systemic illness may also cause hypoplasia of the root structure of the permanent teeth. I recently saw a dog who had severe hypoplasia of most of her roots and some incisors had no roots at all.]

Dogs and cats have a relatively thin layer of enamel compared to longer lived humans. A study (Crossely DA. Tooth enamel thickness in the mature dentition of domestic dogs and cats - preliminary study. J Vet Dent. 12(3): 111 - 113, 1995) found that the enamel of most cat teeth ranges from <0.1 to .03 mm. In dogs, the range for most teeth was <0.1 to 0.6 mm whereas in humans, the enamel on occlusal tables is usually 2 to 4 mm thick.

Enamel is *relatively* non-porous, impervious and smooth and therefore relatively easy to clean and slow to stain. It acts as an effective barrier to prevent bacteria in the oral cavity from reaching the pulp tissues. Enamel has no sensory capacity and so it protects the underlying tissues from mechanical and chemical irritation.

Enamel, though hard, is brittle, tending to shear along the planes of the prisms. A tooth composed entirely of enamel would fracture easily as it has no elasticity or flexibility

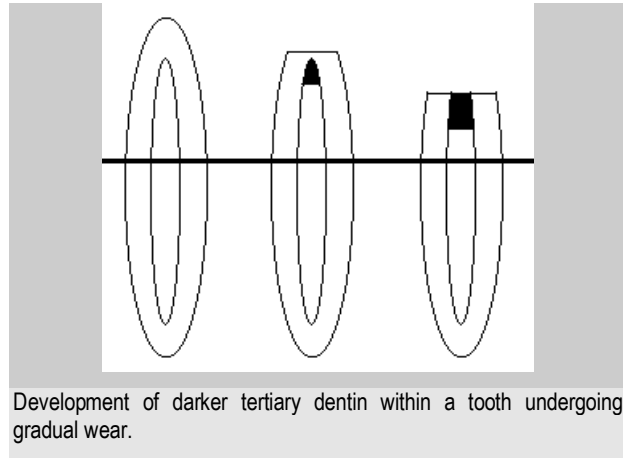
Dentin, which makes up the bulk of canine, feline and human teeth is about as hard as bone but much softer than enamel. It is pale yellow in colour, compared to the stark white of normal enamel. Dentin is roughly 72% mineral, 18% organic matter (mostly collagen) and 10% water by weight.

Dentin is arranged as a collection of tubules running from the pulp towards the enamel. The tubules are roughly 4µm in diameter near the pulp and narrow to 1µm near the enamel.

Lining the inner aspect of the dentin wall is a layer of cells known as *odontoblasts*. These cells extend cytoplasmic extensions into the lumens of the tubules running all the way out to the enamel, therefore, dentin is considered a living tissue. In some of the tubules, unmyelinated nerve fibers lie alongside the

odontoblastic processes and so dentin is a sensitive tissue than can detect heat, cold, touch and variations in osmotic pressure (this is what causes teeth with exposed root dentin to be sensitive to sweets).

Dentin is produced by the odontoblasts on the inside of the tooth throughout the life of the tooth. *Primary dentin* is that dentin which is formed prior to tooth eruption. Normal *secondary dentin* is formed continuously thereafter, causing a gradual reduction in the size of the pulp chamber and is structurally similar to primary dentin. *Irregular secondary* or *tertiary dentin* is formed in areas exposed to injury. It has a distorted collagen pattern, fewer tubules, no nerve fibers and a darker colour than normal dentin.



The collagen component gives dentin some flexibility to allow teeth to withstand considerable forces without fracturing. The overlying enamel may crack and craze, but the dentin can be distorted and return to its normal shape.

A fresh chip fracture of the crown of a tooth will expose dentin with open tubules and nerve fibers. Therefore, the exposed dentin is sensitive to heat, cold, touch and chemical irritation. The open tubules will quickly become colonized with oral bacteria which may propagate through the tubules to infect and kill the pulp. If there is 2 or more millimeters of dentin between the pulp and the fracture site, the odontoblasts under the fracture may have time to produce sufficient tertiary dentin to protect the pulp and prevent an irreversible pulpitis. If there is less than 2 millimeters of dentin covering the pulp, an irreversible pulpitis with pulp necrosis is likely. If you can see a pink hue (known as a *pulpal blush*) through the exposed dentin of a recently fractured tooth, the tooth requires treatment to protect or remove the pulp.

If a tooth wears gradually, due to a chewing habit for example, as the level of wear breaches the enamel and starts to approach the pulp chamber, tertiary dentin is produced as the pulp retreats from potential exposure. If the wear is gradual enough the teeth can be worn down to the gumline without ever exposing the pulp. On the other hand, if the rate of wear exceeds the rate of tertiary dentin production, the pulp will die and further wear will expose the pulp chamber. The exposed tertiary dentin of worn teeth is often brown in colour but is smooth and shiny (wet or dry) and hard. Debris packed in an open pulp chamber is usually dark brown to black, dull when dry and will yield under probing with a dental explorer.

During mechanical abrasion, organic debris becomes impacted into the dentinal tubules, effectively sealing them from the outside world. Therefore, dentin exposed due to mechanical wear will not be as sensitive as dentin exposed by an acute fracture.

The endodontic system of the tooth consists of a *pulp chamber* (in the crown) and one or more *pulp canals* (within the roots). The pulp chamber has *pulp horns* which correspond to the shape of the overlying tooth cusp. With time, the pulp chamber and canals become smaller as secondary dentin is produced. The endodontic system contains the *pulp* which is composed of odontoblasts, fibroblasts, various other cells, blood vessels, lymphatics, nerve fibers and ground substance. In the mature dog or cat tooth, the pulp enters the tooth through many tiny openings in the root apex known collectively as the *apical delta*. There may also be accessory lateral canals further up the root.

The pulp contains unmyelinated fibers which control vasoconstriction in the pulp and myelinated fibers which register pain via the trigeminal nerve.

If pulp is exposed through fracture or decay, it quickly becomes contaminated, inflamed and then necrotic. To salvage the tooth, root canal treatment is indicated. Pulpals may also be damaged by blunt trauma with no crown fracture. As the bruised pulp dies, blood leaks from the vessels and seeps into the dentinal tubules,

causing a discolouration of the crown. Pink, purple or gray discolouration of a crown is another indication for root canal treatment.

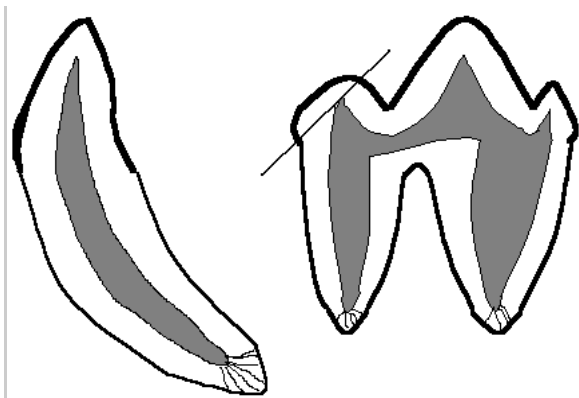
Any tooth with irreversible pulp disease (pulp necrosis), regardless of the cause, is a candidate for treatment. Very simply, the tooth needs to be extracted or it requires root canal therapy. Which treatment is chosen depends on several factors beyond the scope of this article. Leaving an endodontically diseased tooth in place may never cause any externally visible signs, but you can be assured that such teeth are sources of chronic pain and infection and need to be dealt with. When extracting these teeth, it is vital that they be completely removed. I have seen numerous cases of recurrent infra-orbital swelling in which the offending tooth has been previously extracted. On radiographic examination, the cause of recurrence is invariably a retained root tip acting as a contaminated foreign body.

Cementum covers the outer surface of the root. It is in many ways similar to bone and acts functionally as the periosteum for the root. Though physically part of the tooth, it is considered to be part of the periodontal support apparatus.

The cementum at the root apex is cellular (*cementoblasts*) and has some capacity for repair but the cementum near the crown is acellular and has less regenerative capacity. Chronic irritation of the apical periodontal structures can lead to a thickening of the cellular cementum (*hypercementosis*) seen radiographically as a bulging apex. This can arise from traumatic occlusal forces (due to malocclusion or a chewing vice) or from irritation of endodontic (pulp) origin. The bulging root tip can act to lock the root in the socket, making extraction challenging.

Cementum is the tissue to which the periodontal ligament fibers and gingiva attach. These tissues will not attach to enamel, dentin or restorative materials. Therefore, loss of cementum, either by subgingival slab fractures or over-zealous root planning, will prevent gingival and ligament reattachment to the root surface. The result will be a permanently deep periodontal pocket with no hope for reattachment. Periodontal flap surgery (apically repositioned flaps) can sometimes eradicate the pocket to salvage the tooth.

This has been a very brief course on the anatomy and physiology of the tooth. The subject fills many chapters in human textbooks, but what I have offered here should serve as a good foundation for your understanding of disorders of the tooth.



Rough sketches of a canine tooth and mandibular first molar showing coronal enamel (thick black line), root cementum (thinner black line), dentin (light gray), pulp (dark gray) and apical delta (thin squiggly lines at root tips). Note how the pulp extends into the three cusps of the molar and that a small chip fracture on any cusp can lead to pulp exposure and necrosis of the entire pulp.