

WHY I LIKE MONOCRYL™

I do a lot of oral surgery. This includes extractions, fracture repair, tumor resection and periodontal surgery. In almost all cases, I have a wound that requires closure (I suture virtually all extraction sites). So the issue of which suture material to use comes up on a daily basis.

I have experimented with a number of materials and have developed a decided preference for one in particular. That suture material is MONOCRYL. Specifically, I like 4-0 with the P-3 needle (VP# 1651231) and 5-0 with the P-1 needle (VP# 1651234). Here are some of the reasons why:

- Monofilament materials are less likely to harbour and wick bacteria into wound than braided/woven materials.
- Smooth monofilament materials glide easily through tissues with less drag and trauma than woven/braided materials or gut.
- Synthetic monofilaments have more consistent physical properties (strength) than gut. MONOCRYL does not fray and has no weak spots when handled properly.
- Of the absorbable suture materials available to veterinarians, MONOCRYL has a highest initial tensile strength (out-of-package strength).
- MONOCRYL is absorbed by hydrolysis in a consistent and uniform fashion with little or no inflammatory response from the host tissues.
- The rate of absorption of MONOCRYL is more predictable than that of gut. Gut is absorbed by enzymatic activity and so is absorbed more rapidly in febrile patients and in areas of infection or inflammation. This can lead to premature loss of sutures.
- MONOCRYL has 60 to 70% of its initial tensile strength at 7 days and 30 to 40% at 14 days. This means the sutures are likely to last more than a week but I find that many are gone or going from an oral placement in 14 days. That is good, as sutures in the mouth longer than that start acting as foreign bodies.
- MONOCRYL is more pliable than other absorbable synthetic monofilaments and handles nicely with good knot security.
- The P-3 and P-1 needles are very sharp and strong and so easily penetrate even the toughest gingival – the same cannot always be said for lesser needles.
- The 4-0 (for medium to large dogs) and 5-0 (for small dogs and cats) sizes are small enough to leave relatively small holes in the tissues while being strong enough to hold a properly designed flap closed. This is of particular importance in cats where the amount of soft tissue available is quite limited.

Yes, MONOCRYL with a P-3 or P-1 needle is more expensive than regular gut on a regular needle. However, I have had several strands of gut break at the needle after one or two sutures and I have had weaker needles bend and break when suturing gingiva. In the long run, I do not think it costs me more to use MONOCRYL and it does the job better.

WHY DO I SUTURE EXTRACTION SITES?

As I stated above, I routinely suture extraction sites. The only time I do not bother is if the wound has a smaller diameter than the needle I would use to place the material (like a single cat incisor). The reason – closed wounds heal faster and are more comfortable for the patient.

An extraction site is an open wound, with alveolar bone exposed. If such a wound is left open to granulate, food and other debris will find their way into the wound. The result is delayed healing at best and an infected open wound with osteomyelitis at worst. Even if the wound does heal, it is more likely to be a source of pain for the patient than a properly closed wound.

Some will suggest that they leave extraction sites open to drain. That would be fine if you could be certain that the patient would flush the wound with an antiseptic wash and gargle with salt water for one minute twice daily to remove all food and debris from the defect. Since this is not going to happen, the wound should be closed.

Rarely does an extraction site require drainage. In cases where there is significant infection deep into the alveolus, I will curette the alveolus to remove any reactive soft-tissue and surface contamination prior to closing. I will then send the animal home with antibiotics.

A closed wound is far more comfortable for the patient, allowing for a more rapid improvement post-operatively. It also heals much faster, again speeding recovery. Yes, it does take longer to suture extraction sites than not suturing, but that should hardly be an issue. Your clients expect your best work and your patients deserve it.

GUIDELINES FOR EXTRACTION SITE CLOSURE

The first step in closing an extraction site is deciding that you are going to do it. If you decide from the outset that you are going to close the wound, you can plan your incisions and flaps in such a way as to make closure easier. In order to plan ahead, you must keep a few points in mind. These are the basic, underlying principles that should be adhered to in all cases to improve the chances of success.

- There must be no tension on the suture line. If there is tension, you can bet the wound will breakdown.
- Try to arrange things so that the suture line is supported by connective tissue instead of being placed over a void. This is not always possible, but it is always desirable.
- After tying each suture, pull the knot over to one side or the other so that the knot is not directly over the wound.
- Gingiva holds a suture better than oral mucosa. On the other hand, severely inflamed gingiva is very friable and suture material may pull through like piano wire through wet toilet paper. Therefore, wide bites may be necessary to find tissue capable of holding the suture.
- Handle the tissues as carefully as possible to maintain blood supply. Rat-toothed forceps are far better than ones that hold by crushing.
- Elevate your gingival flaps prior to sectioning teeth or contouring bone. Get the soft tissue out of the way so you do not damage it during the other parts of the procedure.
- Use a sharp periosteal elevator to raise your flaps. Several types are available. My preference is the Cislak EX7 Feline Periosteal elevator. I find it fine enough to raise flaps

in cats but substantial enough for much larger flaps in dogs. It is the only style I use – I have three of them.

- Try to avoid vertical releasing incisions whenever possible. Vertical incisions cut across blood vessels and compromise the vascularity of the flap. Instead, try to work with envelope flaps. If you must make a vertical releasing incision, try to place it at the mesial (rostral) edge of the flap instead of at the distal edge.

MORE ON MUCOPERIOSTEAL FLAPS

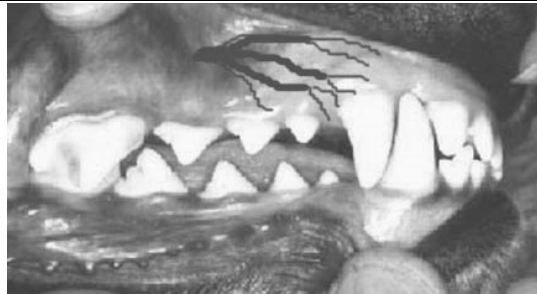In many cases, it is not possible to simply appose the buccal and palatal/lingual edges of the wound. It is necessary to elevate flaps on both sides and to advance the flaps across the defect to meet without tension. Since gingiva has very little give, it is often necessary to elevate the flap beyond the mucogingival junction. The oral mucosa has a far greater capacity to be moved about and manipulated.

The design of your flap will have a great impact on the prognosis for healing. Very simply, oral flaps should be designed with the same principles as cutaneous flaps. These include having a broad base, handling the tissue carefully and undermining sufficiently to allow tension-free closure.

In developing any oral flaps, it is important to understand the blood flow to the region, as it is imperative that adequate blood flow in the flap be maintained.

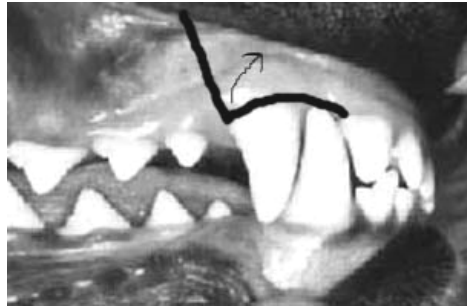
Without getting all anatomical on you, the oral mucosa and gingiva receives its blood from vessels within the soft tissue as well as from vessel that pop up through the bone here and there. An incision that severs the vessels within the soft tissue may not compromise the tissue significantly, if it is left attached to the periosteum and bone so that the sub-periosteal vessels are intact. However, if a flap is raised off the bone, the sub-periosteal vessels are severed and the margin of the flap has lost most of its blood supply.

Arterial blood flow to the oral soft tissues flows from the heart toward the nose: an obvious statement but one that seems to be ignored frequently.



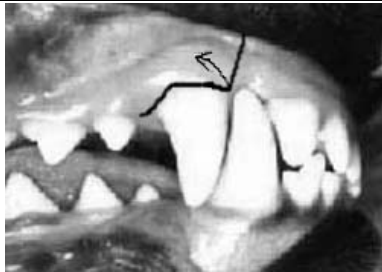
This picture indicates that the blood flow into the maxillary oral mucosa and gingiva comes from dorsal and distal as the infra-orbital artery emerges from the foramen dorsal and mesial to the fourth upper premolar. Keep this in mind.

Many sources suggest elevating a full thickness flap over the root of the maxillary canine tooth to allow for some buccal bone removal to facilitate extraction. Most of the diagrams I have seen depicting this show a vertical releasing incision distal to the canine tooth and then the flap is reflected mesially. This is wrong!!! It severs the vessels within the soft tissue supplying the distal edge of the flap and then elevates that edge off of the bone, severing the sub-periosteal vessels. The result is a severely compromised flap and there is no reason to do it this way.



This is a badly design flap for the extraction of the right maxillary canine tooth. Unfortunately, this is the flap that is depicted in many references. The problem is that the apex of the flap, in fact the entire distal edge has severely compromised blood supply.

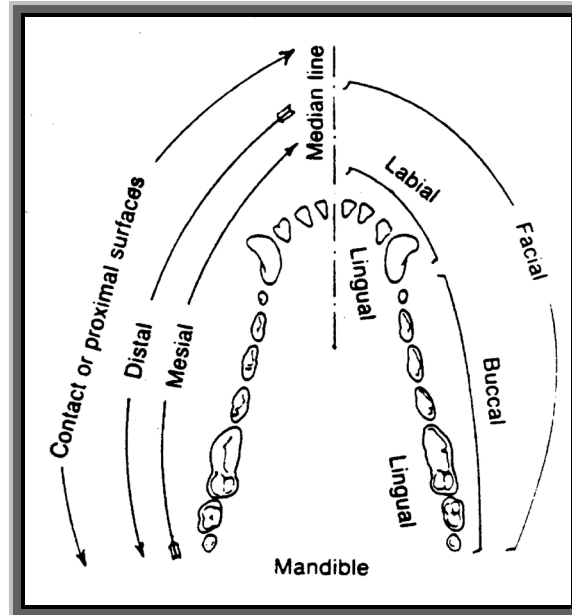
Instead of making the releasing incision distal to the tooth, it should be made mesial to the tooth. Now it can be elevated from the sub-periosteal blood supply because it still has vessels intact within the flap right to the edge. The tissue mesial to the flap is not elevated so it still has its sub-periosteal supply intact.



This is a better flap for extraction of this canine. The tissue mesial to the incision can be left lying on the bone so that its sub-periosteal blood supply remains intact. The raised portion of the flap should still have vessels reaching into the corner. The result will be better vitality of the flap and so better healing.

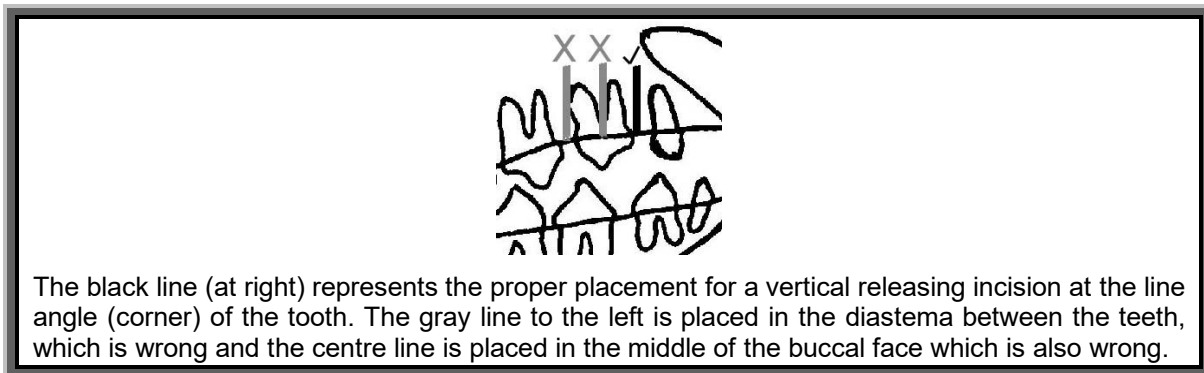
In doing a vertical releasing incision, there is one more rule to consider. The placement of the incision relative to the tooth and gingival sulcus is important. To follow this next bit, I have to explain some anatomical terms.

Each tooth is considered to have four faces. The face against the lips or lining of the cheek is the buccal, facial or labial face (I just use buccal). The face against the tongue (for mandibular teeth) is the lingual face. On the maxilla, the face adjacent to the palate is the palatal face. The face of the tooth closest to the tooth in front (or closes to the mid-line) is the mesial face and the face closest to the tooth behind is the distal face.



The place where two faces meet (i.e. the corner of the tooth) is known as the line angle. Where the buccal face and the mesial face come together is known as the mesiobuccal line angle.

So where should you start your releasing incisions, relative to the tooth? At a line angle.

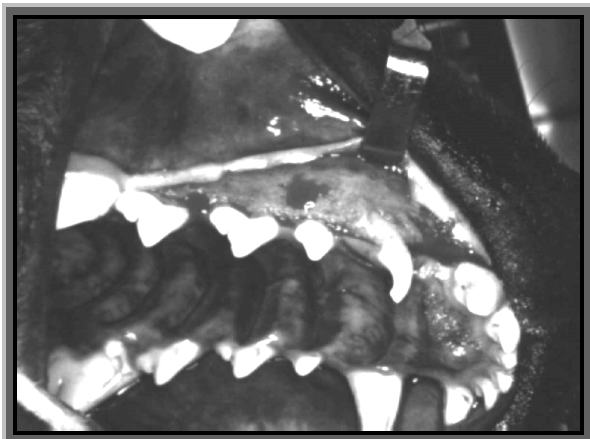


The black line (at right) represents the proper placement for a vertical releasing incision at the line angle (corner) of the tooth. The gray line to the left is placed in the diastema between the teeth, which is wrong and the centre line is placed in the middle of the buccal face which is also wrong.

THE ENVELOPE FLAP

An envelope flap involves no vertical releasing incisions, rather, its incision is horizontal. The incision, generally on the buccal side of the teeth, severs the gingival attachment to the tooth (teeth) and cuts through the gingiva in the interdental spaces. The flap is then elevated from the bone and reflected dorsally (for the maxilla) similar to reflecting a straight cutaneous incision.

An envelope flap is most conservative of the vasculature and can be extended mesially and distally intra-operatively if more exposure is required. A vertical releasing incision cannot be moved mesially or distally once you make your cut. Therefore, with an envelope flap, you can start with a conservative (small) flap and extend it as needed to allow adequate exposure and tension-free closure.



This picture shows a rather large envelope flap extending from the distobuccal line angle of tooth 107 to the mesiobuccal line angle of tooth 103. The flap was raised to allow removal of some teeth and then a rhinotomy to remove a compound odontoma that was situated in the right nasal cavity. The incision is parallel to the blood supply and within gingiva for its entire length. Since the flap extends beyond the mucogingival junction to involve the maxillary oral mucosa, it was easily advanced to meet the palatal side of the incision without tension.

If the defect to be closed is large (as in after removing a lot of tissue to excise an oral mass), it may still be difficult to advance and envelop flap far enough to get tension-free closure. To get more advancement from the flap, you can elevate further and/or incise the periosteum at the base of the flap.

The downside of the envelope flap is that it involves elevating the gingiva from teeth either side of the surgical site – teeth that are going to be left in the mouth. This compromises the periodontal status of these teeth. If the flap is elevated and replaced carefully, the gingiva should reattach to the teeth left in and the normal periodontal relationships should be re-established. However, it is wise to assume that elevating and replacing a flap in this manner may lead to the loss of about 1 millimeter of alveolar crestal bone. For most teeth, the loss of one millimeter of bone is of little significance and so this is a price I am willing to pay in order to improve the prognosis for healing of my flap.