

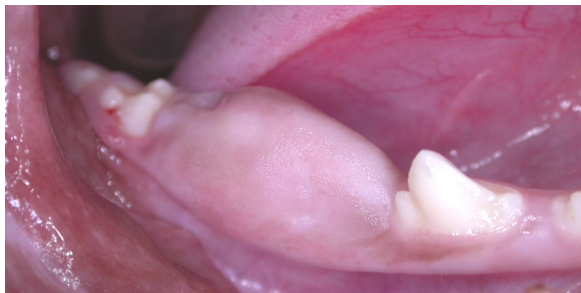## FOCUS ON: PARTIAL AND SOFT-TISSUE IMPACTIONS

I have previously written about teeth that are completely embedded (un-erupted, impacted) and the dentigerous cysts that can form around these teeth. (<http://www.toothvet.ca/PDFfiles/MissingTeeth.pdf>). I would now like to discuss a different form of impaction that I have seen quite a bit of in the last few years. That would be partial impactions and soft tissue impactions of both deciduous and permanent teeth.

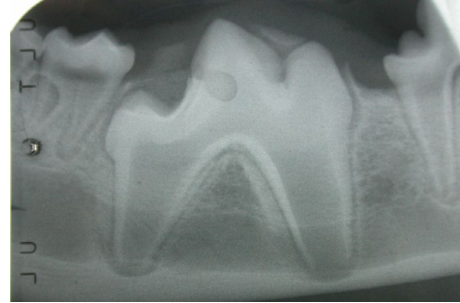Sometimes the gingiva overlying an erupting tooth is too thick and fibrous for the tooth to cut through. Okay, maybe that is an oversimplification. Maybe there is a defect in the programmed cell death that should allow a window in the gingiva to open up and the tooth to pop through. Either way, the tooth becomes totally or partially impacted below a layer of thick fibrous gingival tissue.

Let's look at the case of Winnie, a seven-month-old Bedlington terrier. The clinical photos were taken by me on the day of assessment/treatment. The pre-operative radiographs were all taken by the referring veterinarian a few weeks prior at ovariohysterectomy. The films were then sent to me so that I could assess and start working on the treatment plan and estimate before the patient arrived at my office.

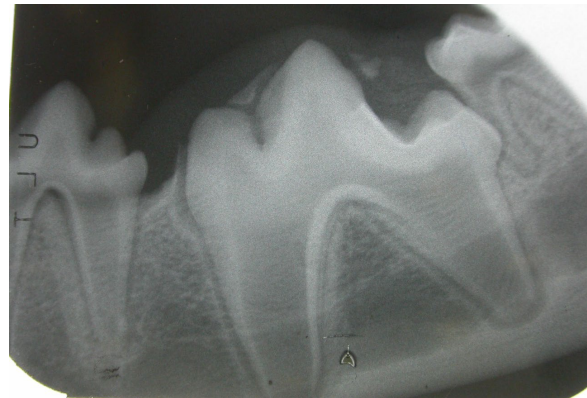
In the photo below, we can see a hummock of gingiva rising up as the right mandibular first molar is trying to break through but is failing.



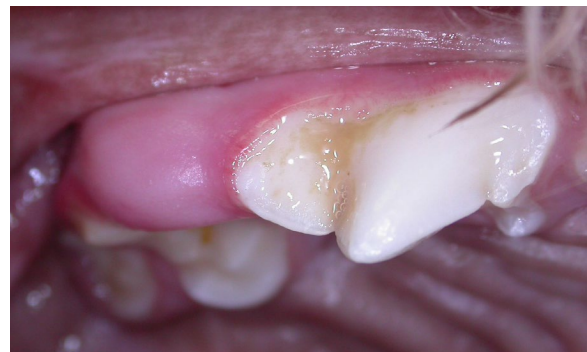Next is the radiograph of that situation. Not only was there tough soft tissue covering the entire crown, there was also some bone still overlying the crown of the tooth. As the roots were developing and getting longer, they were growing ventrally out of necessity (if the crown cannot go up then the roots have to go down).

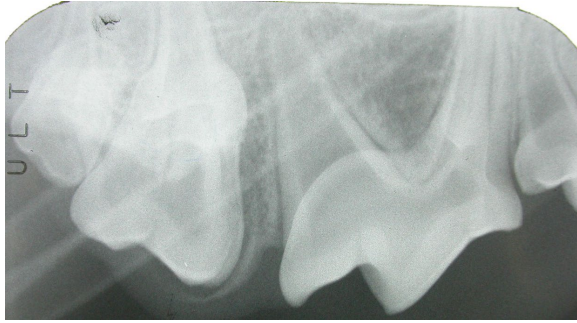


And that situation was bilateral. Here is the film of the left mandibular first molar.

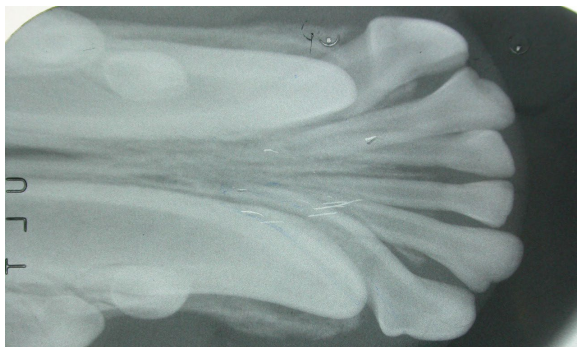
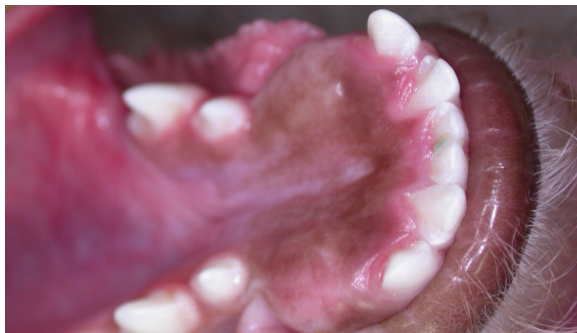
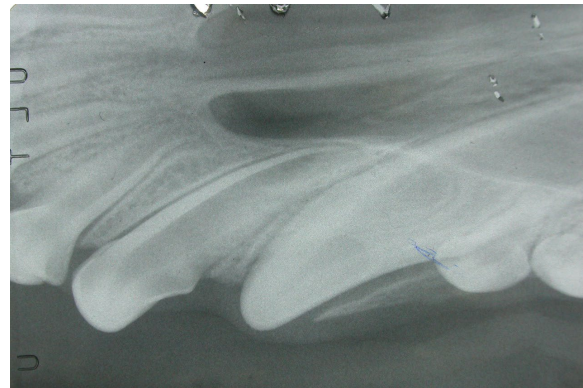
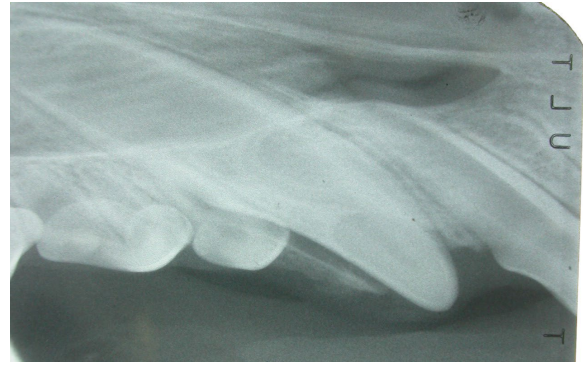The right maxillary first molar had largely erupted, but the mesiobuccal cusp was still buried below gingiva and bone as seen in the clinical photo and radiograph.

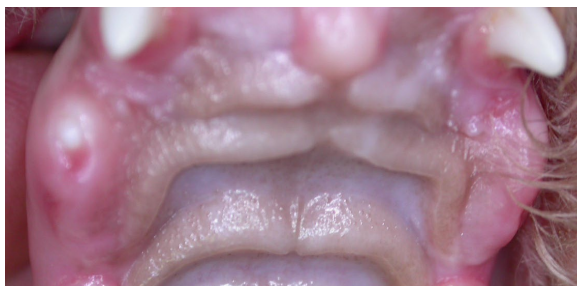




The lower canines presented with an extra challenge. Not only were they impacted below tough gingiva, they also seemed to be positioned too lingually and were having their eruption path obstructed by the lower third incisors as seen on the radiograph.



The upper canines were simply not erupting. The right had managed to poke its tip through the gingiva, but both were still trapped and going nowhere in a hurry.



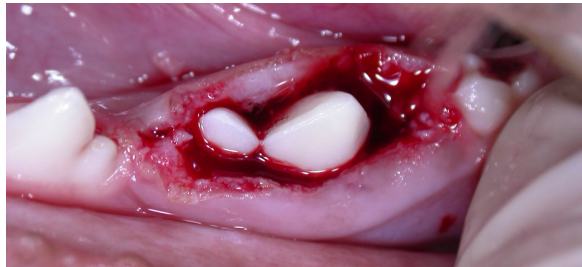
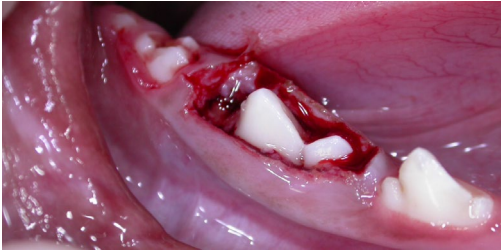So, what do we do about all this? What we do not want to do is ‘wait-and-see’. The roots of the lower molars are already about to break through the ventral cortex of their respective mandibles. The canine roots are growing distally into the maxilla. We want to give these teeth the opportunity to erupt normally when their potential to respond to that opportunity is greatest – during root development. Once the root has finished growing and the periodontal support for the root has matured, there is less likelihood that a tooth will erupt on its own even if all the barriers are removed. So, we want to act fast.

The goal of treatment is to remove or reduce the resistance to eruption and allow these teeth to erupt unaided (i.e., without the aid of orthodontic appliances). This is accomplished by performing an operculectomy over the crown of each unerupted or under-erupted tooth. Essentially, this is surgical removal of the gingiva and any bone overhangs that are impeding eruption while preserving sufficient gingival

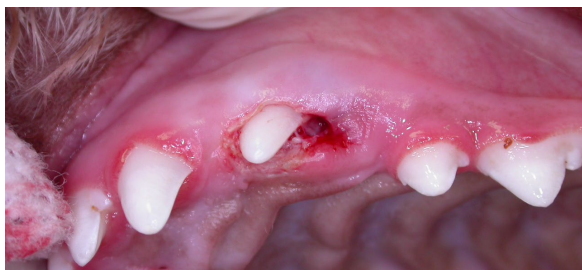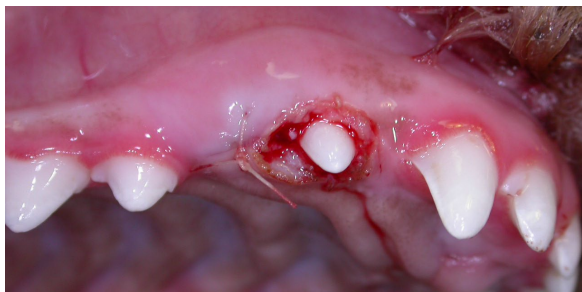


tissue to provide proper periodontal support for the tooth once it has erupted.

Here are post-op photos of the lower first molars.

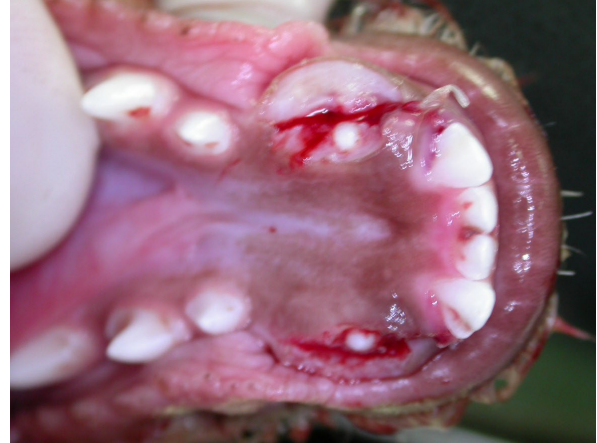

The upper canines also had operculectomies to expose the crowns. On the right, I reflected a gingival flap to expose the bone, allowing me to widen the opening at the top of the socket so that the erupting crown could pass through. I then lightly sutured the flap closed. I did not want to suture tightly around the crown of the canine tooth as this would have increased resistance to eruption and that was the last thing we wanted.

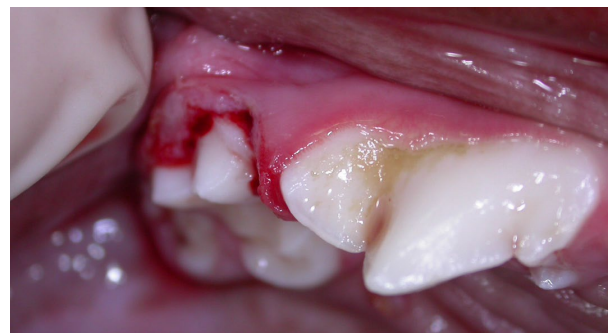

The lower canines not only had gingiva and bone blocking their eruption. Those third incisors were also a problem, so I extracted them and exposed the canine crowns as shown.

Like so many dental issues in young dogs, “wait-and-see” is the wrong approach. These impactions need timely treatment to allow for a desirable outcome.

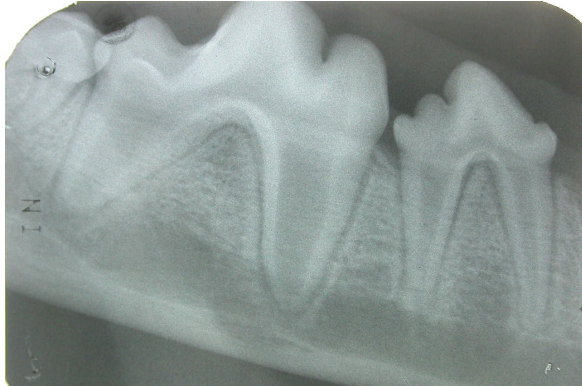
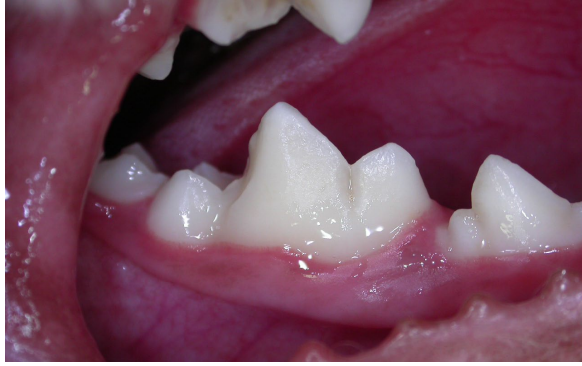
The right upper first molar just needed a little redundant gingiva and bone removed to expose that one last cusp.

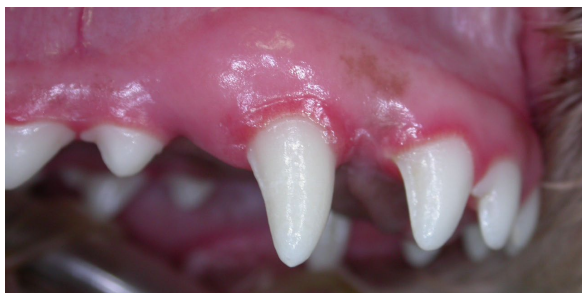
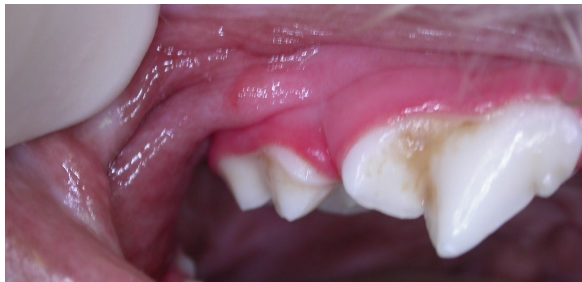
Now, none of these procedures *make* anything happen. They are intended to allow or encourage proper development. The next step is sit back and see how things turn out.

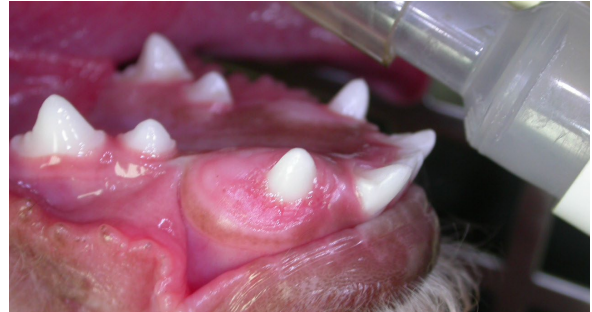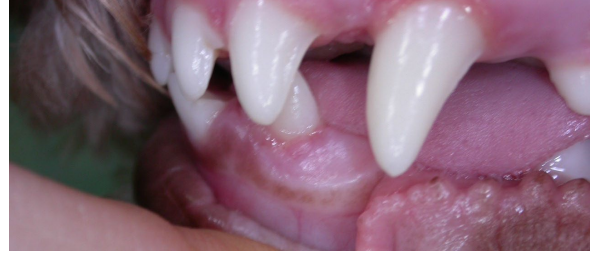Six weeks later things looked like this! Below is the right lower first molar. The left lower first molar looked just as good.



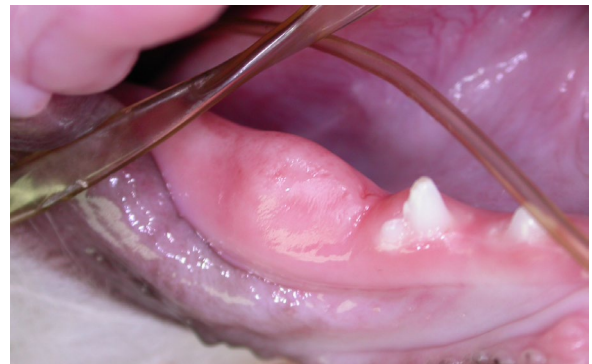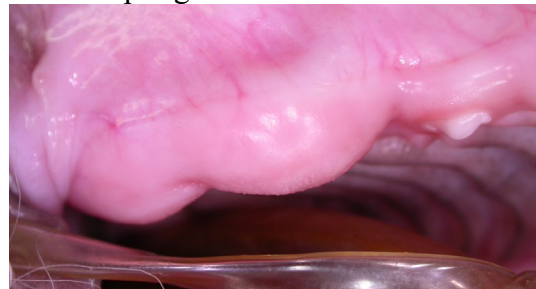
Next are photos of the right upper first molar and canine teeth. The canine is not yet fully erupted but it is well on its way.



At time of writing, the lower canines are still under-erupted as their path was being blocked by the upper third incisors, which have since been removed. I expect this will do the trick.

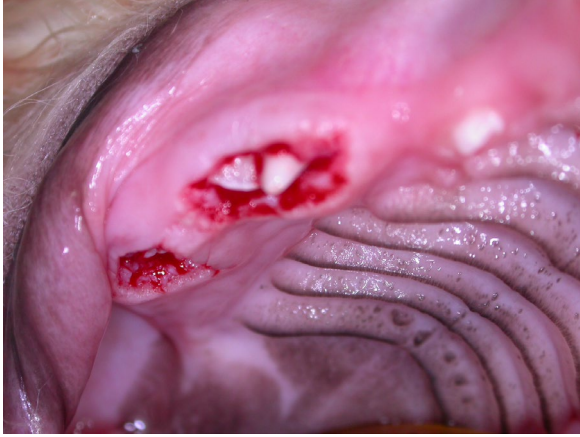

And here is a case in a younger dog having trouble erupting the deciduous dentition.



The same treatment is indicated – operculectomies to expose the crowns and reduce the resistance to eruption.....





then warn the owners that the molars have no deciduous precursors to blaze a trail through the bone and gingiva and since this dog had trouble erupting the deciduous teeth, there may be trouble with the eruption of the permanent teeth. More surgery may be needed around six-months of age.