

PERICORONITIS?

I have discussed unerupted teeth and their consequences in the past (www.toothvet.ca/PDFfiles/MissingTeeth.pdf and www.toothvet.ca/PDFfiles/dentigerouscysts.pdf). In this piece I would like to explore the *under-erupted* tooth and the liability it presents. Before we do that, I would ask that you review the normal and desirable periodontal anatomy as outlined in the following: www.toothvet.ca/PDFfiles/PerioAnat&Physio.pdf.

The important points of the normal periodontal anatomy for this discussion are:

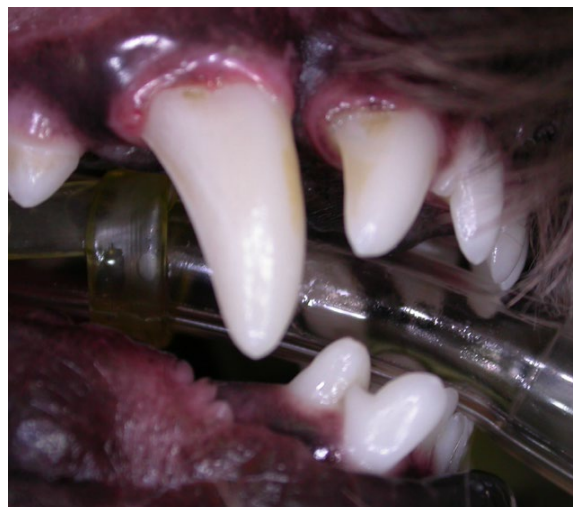- gingiva and periodontal ligament will only attach properly to bone and cementum

- the gingival should be firmly attached to the cementum in the area between the top of the bony socket and the cementoenamel junction

- the free gingival margin is normally just slightly coronal to the cementoenamel junction

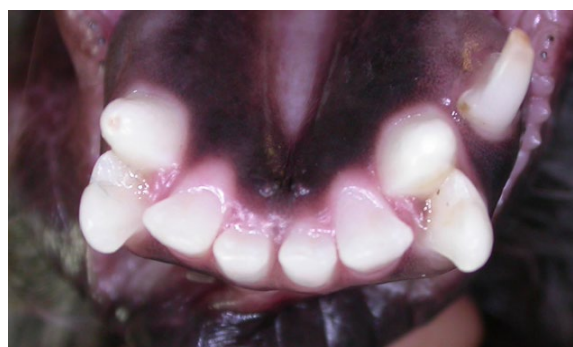- the free gingival lies against but does not attach to the enamel resulting in a space between gingival and enamel known as the gingival sulcus. The normal depth of the gingival sulcus will depend on the size of the patient and the size of the tooth. For a canine tooth in a large dog, the gingival sulcus may be 3 millimeters. For the second maxillary molar in a 1.5kg Yorkie, anything over 0.5 millimeters would have me worried. Have a look at this - <http://www.toothvet.ca/PDFfiles/probing.pdf>.

Now we need to consider the situation that may occur if a tooth fails to erupt fully. This is a very common problem for the canine teeth in small, brachycephalic dogs (Boston terriers, pugs, shih tzus..). Sometimes the tooth is prevented from erupting properly by a malocclusion or crowding issue. Sometimes it remains under-erupted for no apparent reason (just another cost to the animal of selective breeding based on "cute" rather than on "healthy").



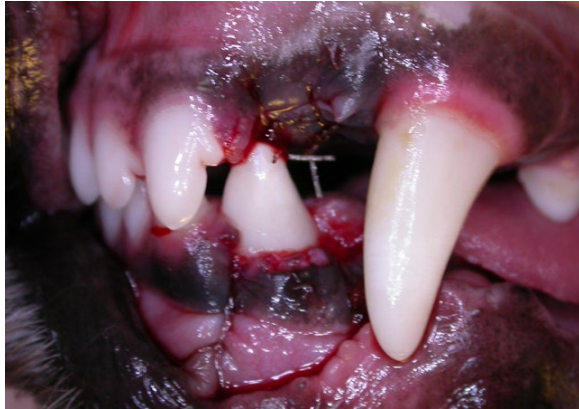In the above photo of a 14-month old terrier, we can see that the upper canine tooth has erupted well and fully, but there is trouble with the lower canine. This dog's teeth are just too big for the small mouth. Therefore, the diastema (space) between the upper third incisor and canine tooth is too narrow to accommodate the lower canine tooth. Also, crowding of the lower canines and incisors has the lower canine's eruption path blocked by the third incisor.

The next photo shows that crowding issue again as well as a persistent left primary canine tooth adding to the challenges. There just is no room for the large lower canine tooth to erupt properly so about 70% of the crown remains subgingival. Left untreated it would be very likely that bacteria would colonize the very deep 'gingival sulcus' resulting in a chronic pericoronitis. This would then have given rise to periodontal disease as the infection extended down the root of the tooth.

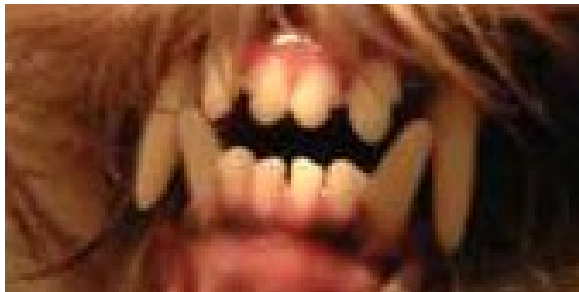


We need to get these canine crowns out in the open where they belong. While the dog was a little old for me to have great faith that they could erupt further on their own, we decided to give them a chance. Treatment involved removal of the persistent lower left primary canine tooth and the third incisor in each quadrant. The lower third incisors were removed

because the lower canines were bumping up against the back of their roots. The upper third incisors were removed to open a wide enough diastema.



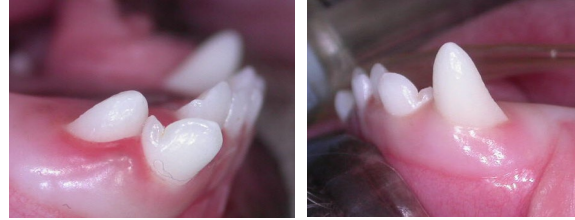As well as the extractions, I attempted to move the gingiva apically as I closed the wounds to lengthen the crowns as bit. Then I sent the dog home to see what the lower canines would do now that there was nothing blocking their way. I did not see Rudi again, but a few months later, the referring veterinarian sent me this photo.



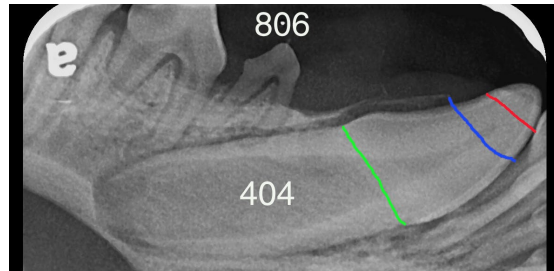
I was both surprised and very happy to see how the lower canines did exactly what we wanted. They erupted fully, bringing the enamel out in the open.

Not all patients are so lucky. Not all patients get treatment in a timely manner, when there is still potential for the canines to erupt once the physical obstructions are removed. Sometimes there really is no identifiable or treatable reason for the tooth to have stopped erupting and so nothing can be done to get it to erupt on its own. In such cases, if the situation is mild, crown lengthening surgery can be performed (See Hale FA. Crown Lengthening for Mandibular and Maxillary Canine Teeth in the Dog, J Vet Dent, 18(4) 219-221, 2001). In more severe under-eruptions, an orthodontic appliance may be employed to extrude the tooth or it may require extraction.

Here is another case, this time in an 8-month-old shih tzu.



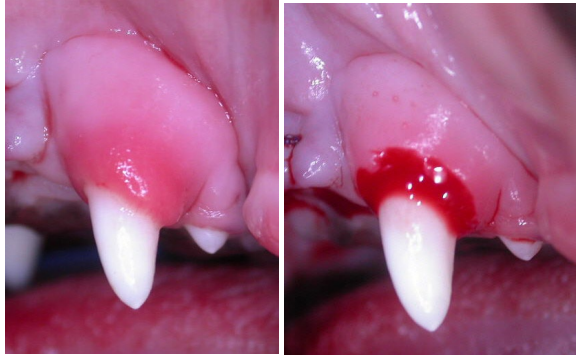
The left lower canine is not doing too badly, but it still needs to erupt further. On the right side, the lower canine is badly under-erupted and is riding up the back of the third incisor. Radiographically...



The green line depicts the cementoenamel junction. The blue line is the top of the alveolus and the red line is the gingival margin. Also of note, there is no adult lower left first premolar (405) or second premolar (406) but there is a persistent primary second premolar (806) evident in this image.

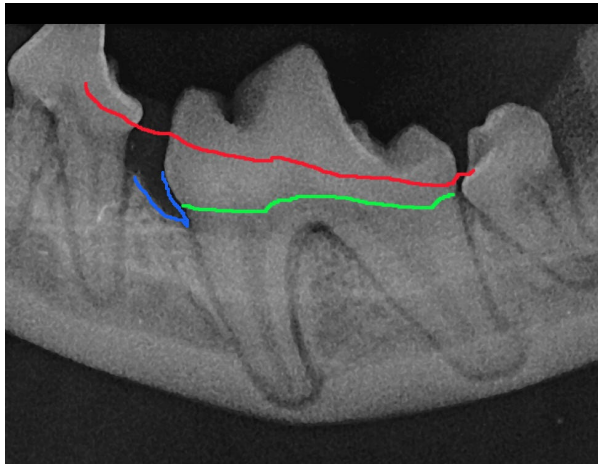
Treatment for the under-eruption of the lower canines was removal of the lower third incisors to alleviate any physical impediment they might have posed to the eruption of the canine teeth. Now we have to wait and see how things work out. By the way, there was loads of other issues to deal with in this mouth, as with virtually all young shih tzus.

On the next page we have another shih tzu (9-months-old this time) and we are looking at the left maxillary canine tooth. In the first view, we can see there is loads of gingiva but a fair amount of it is already inflamed (pericoronitis). Since there is an abundance of gingiva, gingivectomy as a crown lengthening procedure was indicated. See www.toothvet.ca/PDFfiles/gingival_hyperplasia.pdf for more details on that procedure. Please understand that the ONLY time it is acceptable to amputate and discard gingiva is when there is too much of it. In the vast majority of periodontal cases, great efforts are made to preserve as much gingiva as possible. Also, when doing gingivectomy/gingivoplasty, you **must** respect biologic width as outlined in the linked article above.



As well as the canine teeth another common area for trouble in really small dogs is the mesial aspect of the lower first molar tooth. Often crowding and ventral bowing of the mandibles results in the lower first molar being tipped forward with the mesial aspect under-erupted.

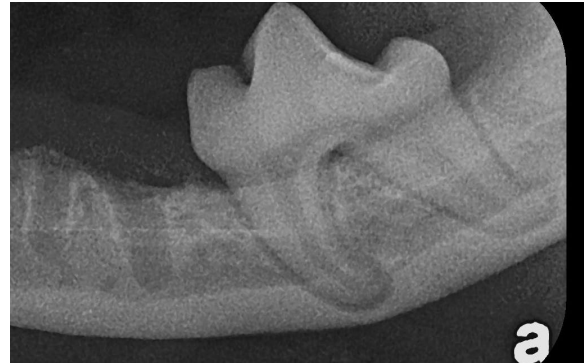
In the radiograph of the left mandible of this same 9-month-old shih tzu, the green line depicts the cemento-enamel junction and the red line the gingival margin. Considerable enamel is subgingival mesially and there is a vertical defect in the alveolar bone (blue line). This anatomic situation sets up a perfect opportunity for the early development of periodontal disease in this location. Left unattended, chronic infection within the defect would result in progressive bone loss down the length of the mesial root of the first molar, effectively cutting the mandible in half, resulting in a high degree of risk for pathological fracture at this site.



No amount of dental diet, chew-treats or tooth brushing is going to reach into this defect and keep it clean so unless this individual is blessed with far-better-than-average natural resistance to periodontal disease you can bet on pericoronitis leading to periodontal disease with possibly disastrous results. And do not expect that there will be any outward signs of trouble to tip you off – have a look at this

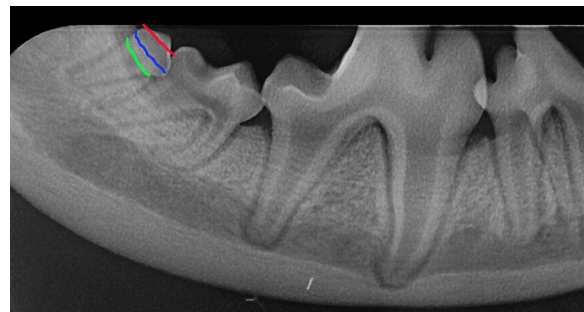
paper from a previous issue of The CUSP to see why visual inspection is not enough - www.toothvet.ca/PDFfiles/perio_hidden.pdf.

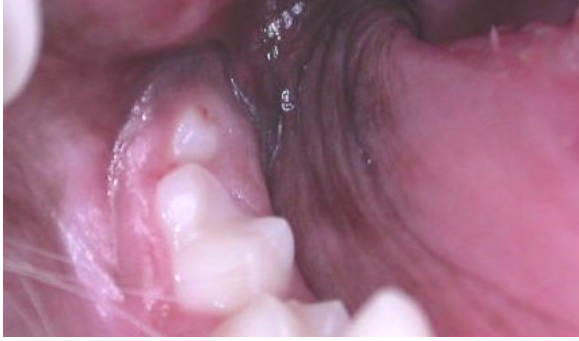To prevent serious problems in the future and to give a reasonable prognosis for this important first molar, we need to change the anatomy of the area. The post-operative radiograph shows the immediate result.



The fourth premolar has been removed (as has the second molar). Then I removed some of the bone mesial to the molar to bring the height of the dorsal mandibular ridge below the cemento-enamel junction. With the gingiva sutured closed around the molar, proper periodontal anatomy/biologic width can be established and this tooth now has a fighting chance. The dog is still a shih tzu, still needs daily dental home care (tooth brushing, etc.) and still should have annual COHATs (comprehensive oral health assessment and treatment), but at least now the anatomic risk factors for the development of periodontal disease have been reduced.

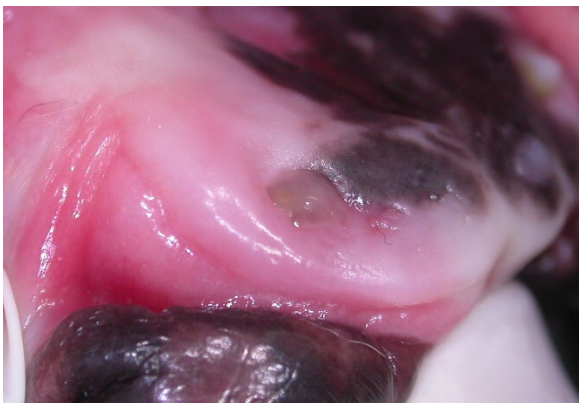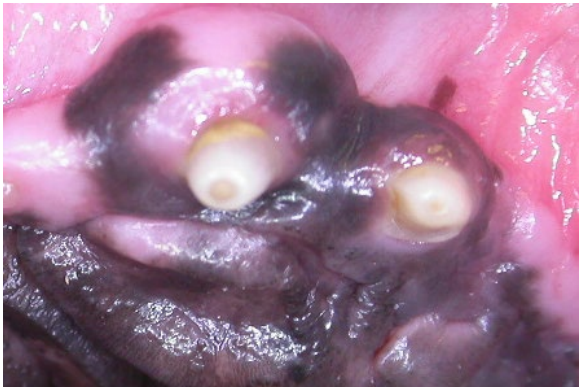Any tooth can be under-erupted. In humans, the most common would be the wisdom teeth. This radiograph of the right mandible (the 8-month-old shih tzu again) shows a similar situation. There are just too many teeth for the length of the mandible and so the last (third) molar is protruding from the junction between the ramus and the body of the mandible and is under-erupted as seen in the photo.



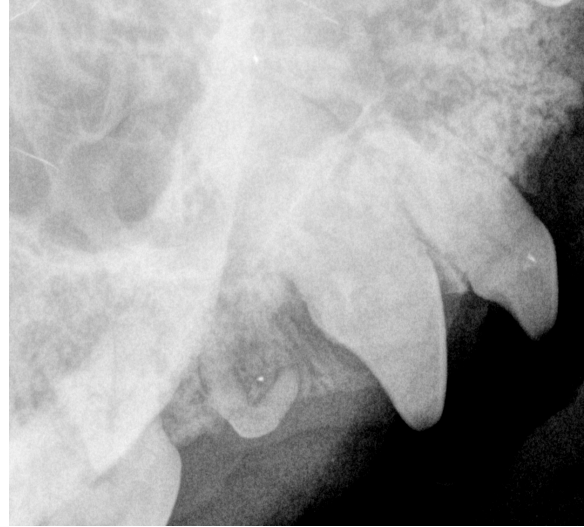

It looks like the tooth has erupted, but when you compare how big the crown looks clinically to how big it is radiographically, it becomes apparent that much of the crown remains un-erupted. This tooth represents a subgingival plaque-trap and it needs to be extracted for the same reason many human wisdom teeth are removed – pericoronitis.

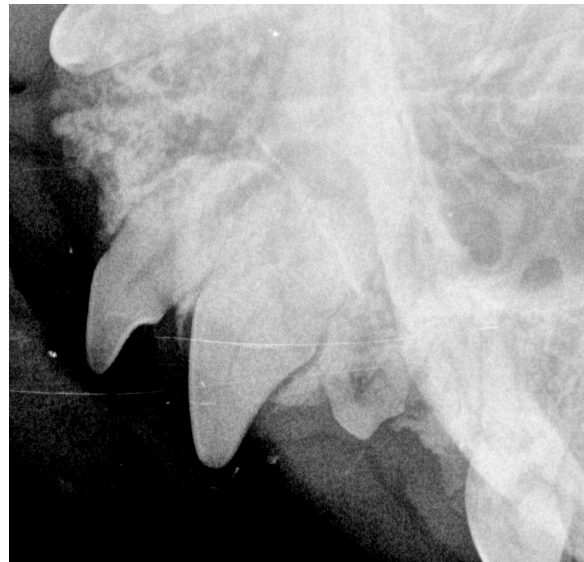
Update: Now I will share a case of pericoronitis that did not get detected or managed until the dog was eleven years old. It was an 8 kg Boston terrier. He had all four canines but the upper ones were significantly under-erupted and the lower ones were only just poking through a small hole in the gingiva as shown in the following images.



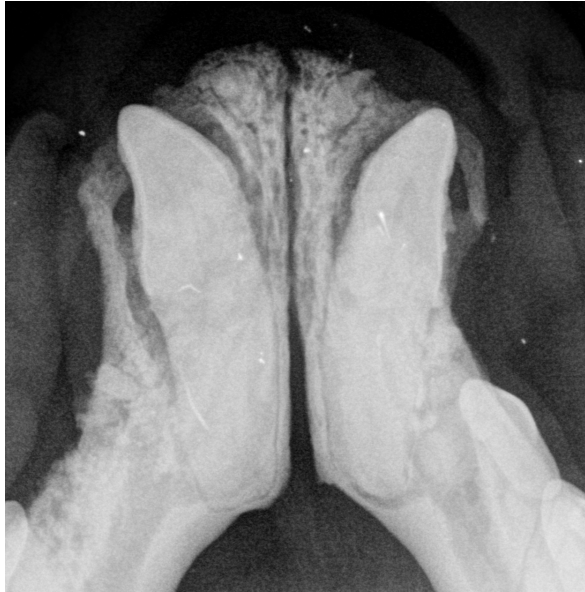At first I thought the upper canine was a primary tooth because it was so small. But here are the radiographs.



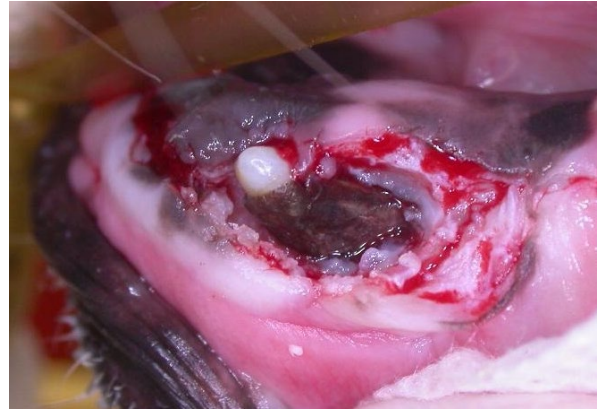In the right maxillary view we can see a completely developed adult canine tooth with most of the crown still within the bony socket and a lot of bone loss around this tooth. Then the adult 1st, 2nd and 3rd premolars are missing and the primary 2nd premolar is still in place.



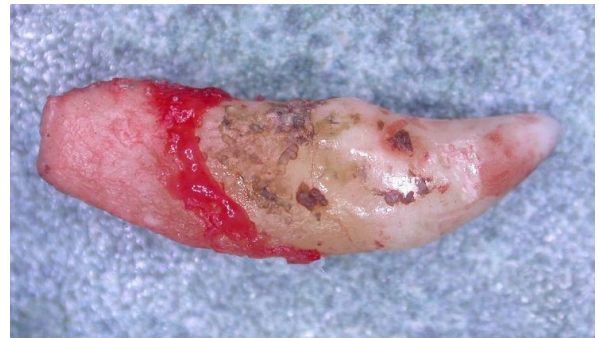This view of the left maxilla shows much the same situation with some exceptions. This canine tooth does not seem to have developed significant pericoronitis. The pulp chamber in the 3rd incisor is very large compared to all the other teeth and the age of the dog, indicating that the pulp in this tooth died years ago (I don't know why). Here is a paper explaining pulp chamber size and pulp vitality - http://www.toothvet.ca/PDFfiles/endo_dx.pdf.



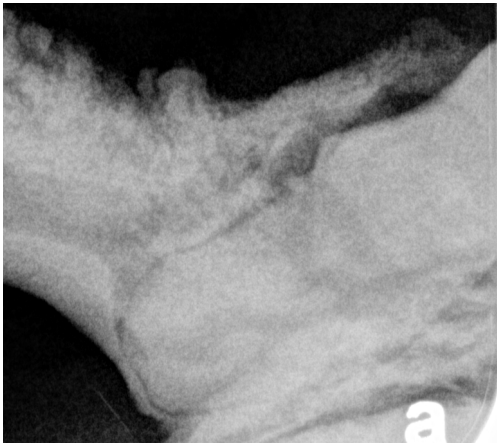The lower canines both have deep pockets of chronic infection and inflammation around the buried crowns and the right canine (on the left in the above image) has a periodontal pocket going half way along the root (and there are two retained incisor roots to remove as well).



Upon reflecting the flap to start the extraction of the lower left canine tooth, I found the buried part of the crown completely covered in calculus.



This is the extracted lower right canine. Much of the coronal calculus was knocked off in the process of extracting the tooth. You can see the extent of attachment loss and calculus going half way down the root of the tooth.



Above is a lateral view of the lower right canine tooth and below is the lower left canine tooth.

This dog had no obvious external signs of trouble with these under-erupted canines. As with most periodontal disease, it was hidden from view, but this dog had suffered in silence for years.

And by the way, he had end-stage periodontal disease of his upper 4th premolars so these also had to come out.

So, get in the habit of looking for under-eruption, particularly and small, brachycephalic breeds and be pro-active. Get the problem treated ASAP. You want to remove obstructions to eruption while the teeth still have the potential to erupt and/or do the necessary crown-lengthening procedures before pericoronitis and periodontal disease become established.

