

HALE VETERINARY CLINIC

Fraser Hale, DVM, FAVD, DiplAVDC

BOARD-CERTIFIED
VETERINARY DENTIST™

DENTAL AND ORAL SURGERY FOR PETS SINCE 1991

I thought you might be interested in seeing what a set of normal cat dental radiographs looks like. The following pages contain the images captured from a six-year-old domestic short hair with no radiographically detectable dental pathology. In other words, this is a really boring set of radiographs and that is what we hope all of our patient will have. For orientations I have labelled each tooth with its Modified Triadan number as illustrated below.

PHONE
519-822-8598

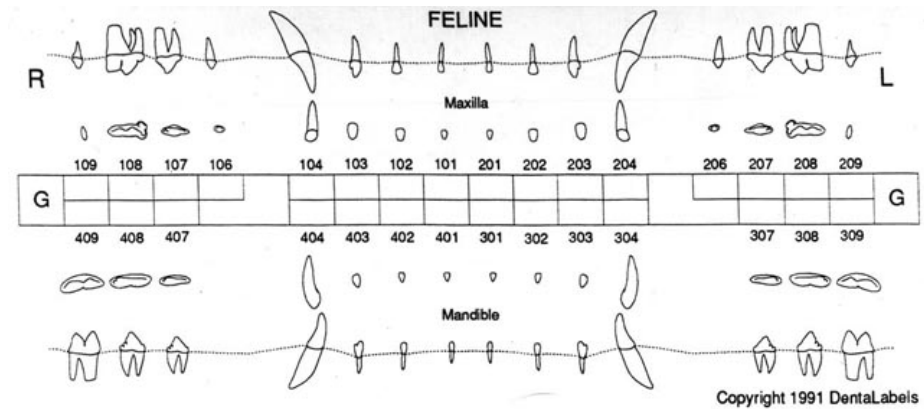
FAX
519-763-6210

EMAIL
info@toothvet.ca

WEB SITE
www.toothvet.ca

ADDRESS
159 Fife Road,
Guelph, ON N1H-7N8

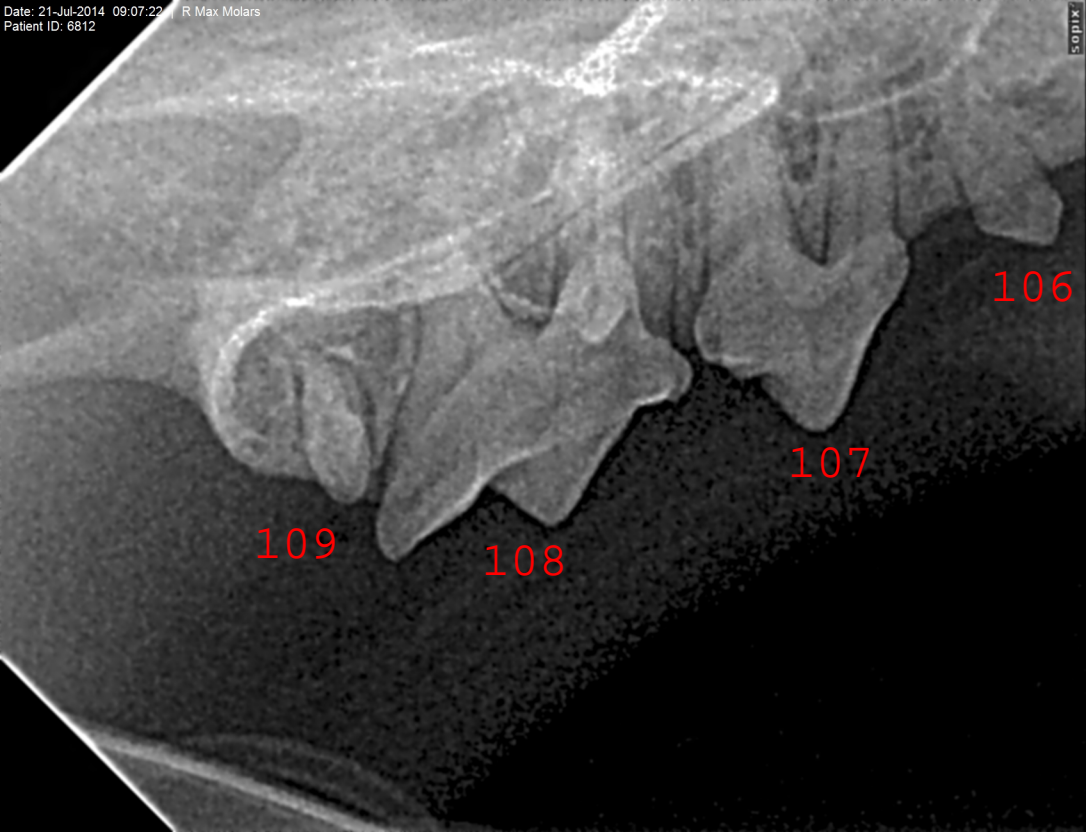
OFFERING
ROUTINE AND ADVANCED
VETERINARY DENTAL SERVICES
IN THE FOLLOWING AREAS
ENDODONTICS
ORAL MEDICINE
ORAL SURGERY
ORAL & DENTAL RADIOLOGY
ORTHODONTICS
PERIODONTICS
PROSTHODONTICS
RESTORATIONS



Regards,

Fraser A. Hale, DVM, FAVD, Dip AVDC

Hale Veterinary
Professional Corporation

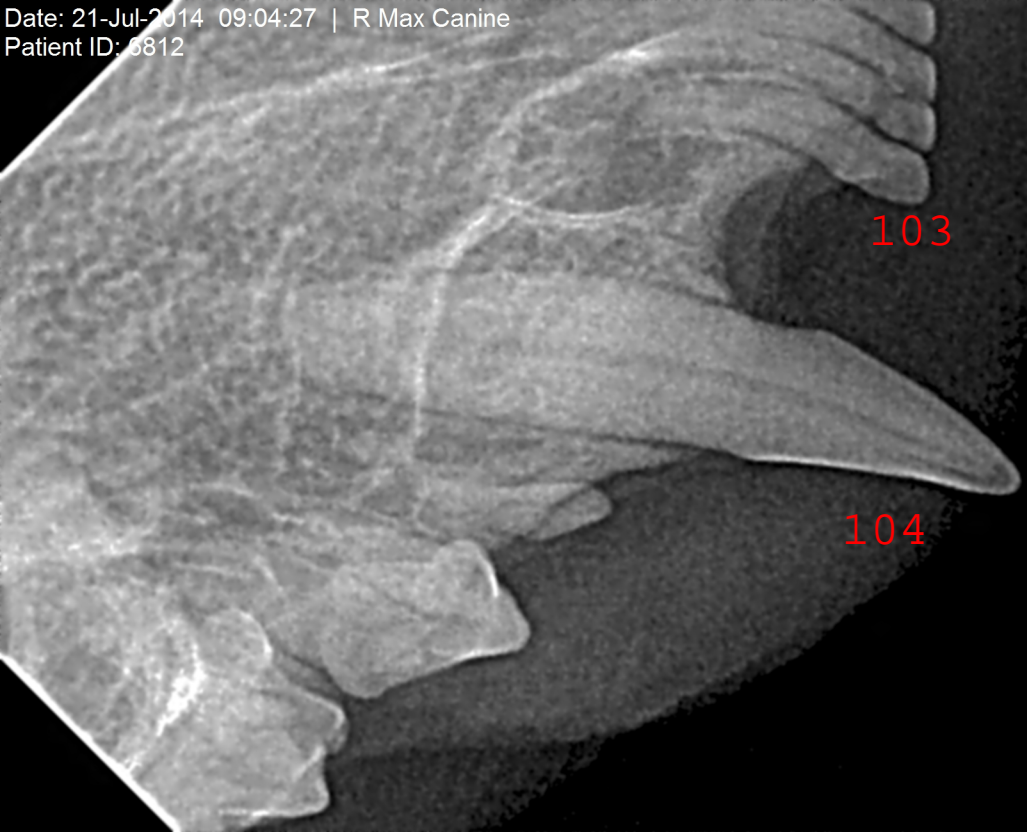


106

107

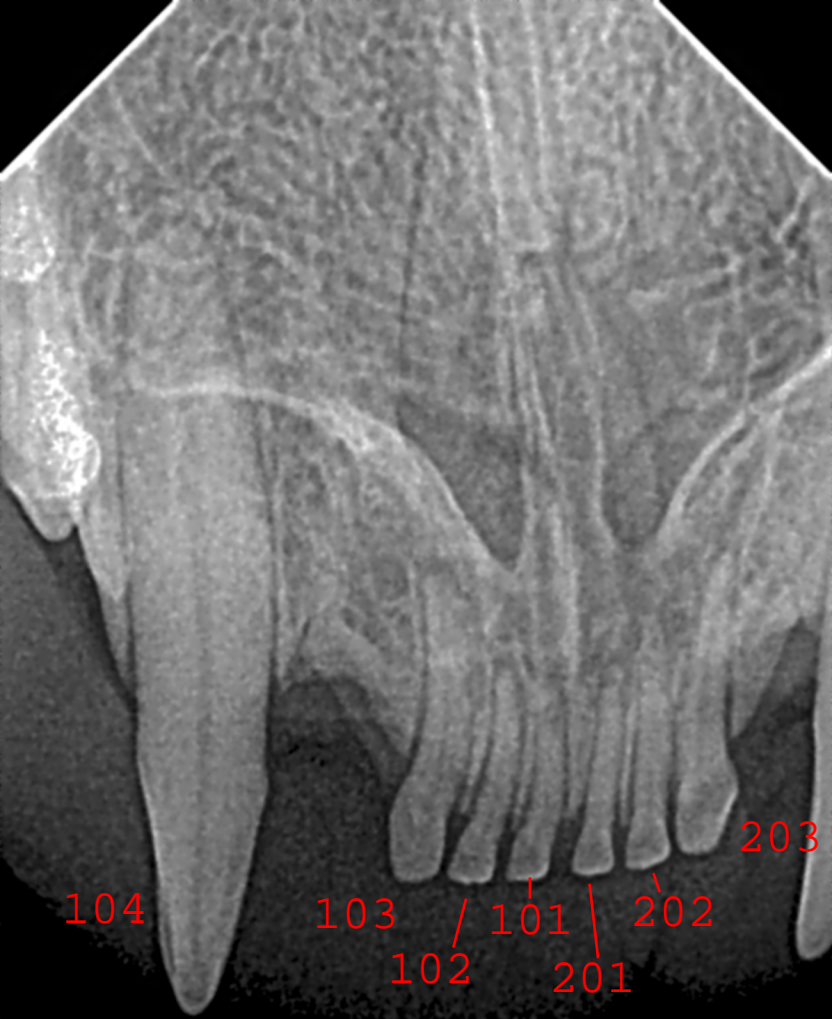
108

109

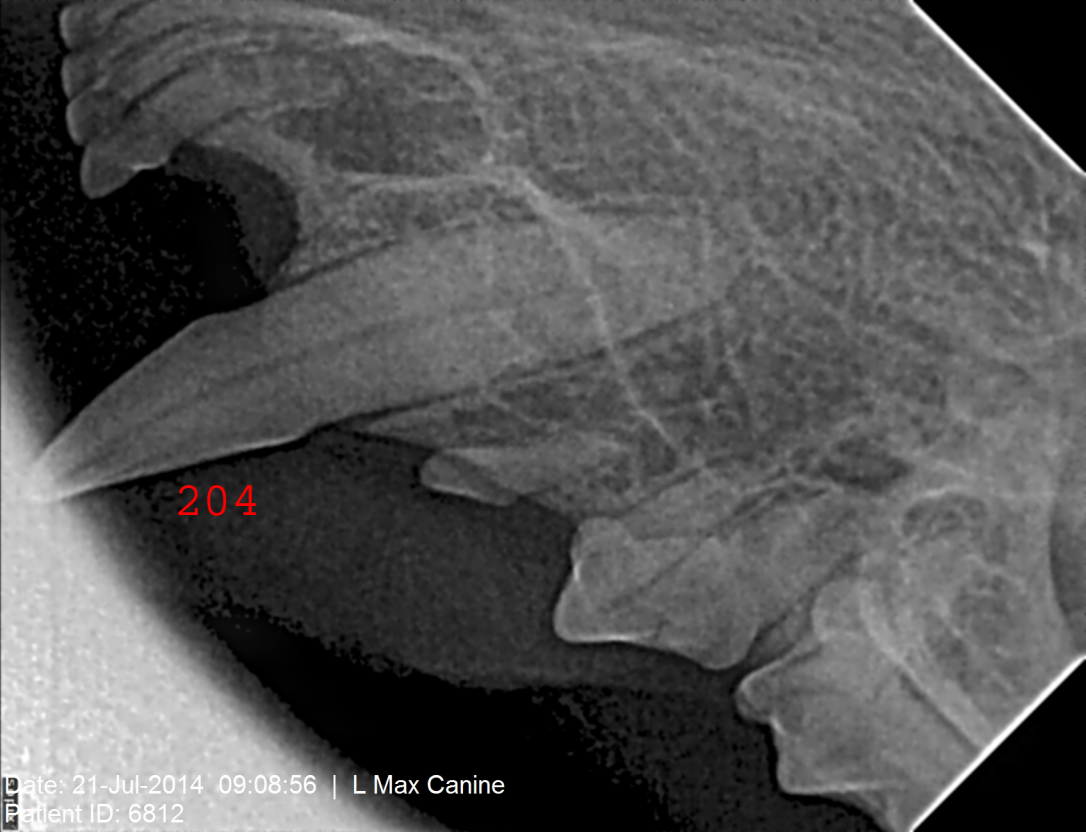


103

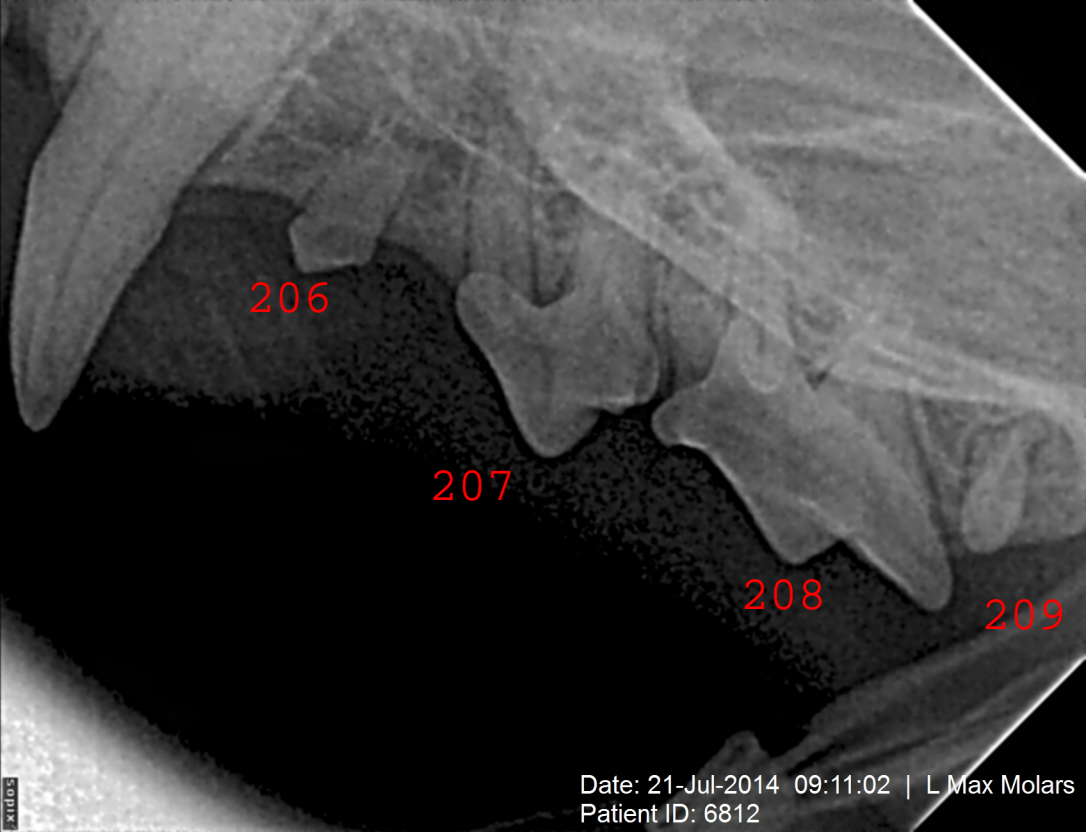
104



Date: 21-Jul-2014 09:04:51 | Max Incisors
Patient ID: 6812



204



206

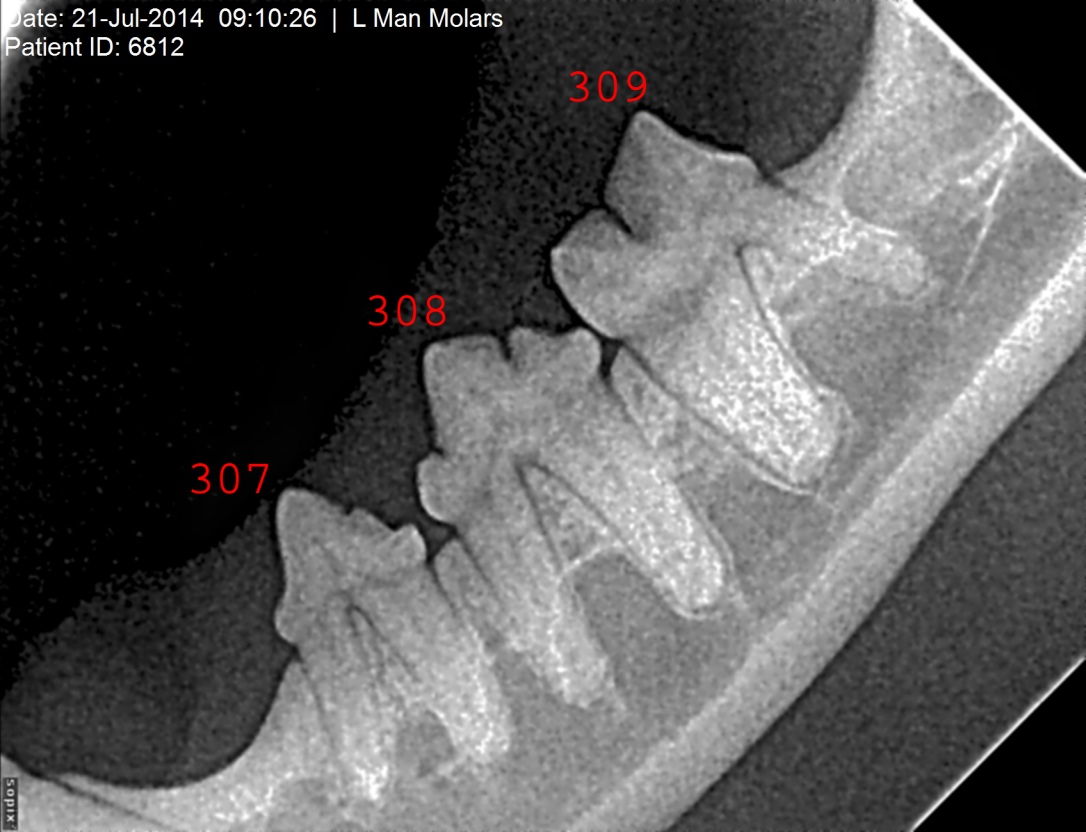
207

208

209

Date: 21-Jul-2014 09:11:02 | L Max Molars
Patient ID: 6812

xipix



309

308

307

404

403

401

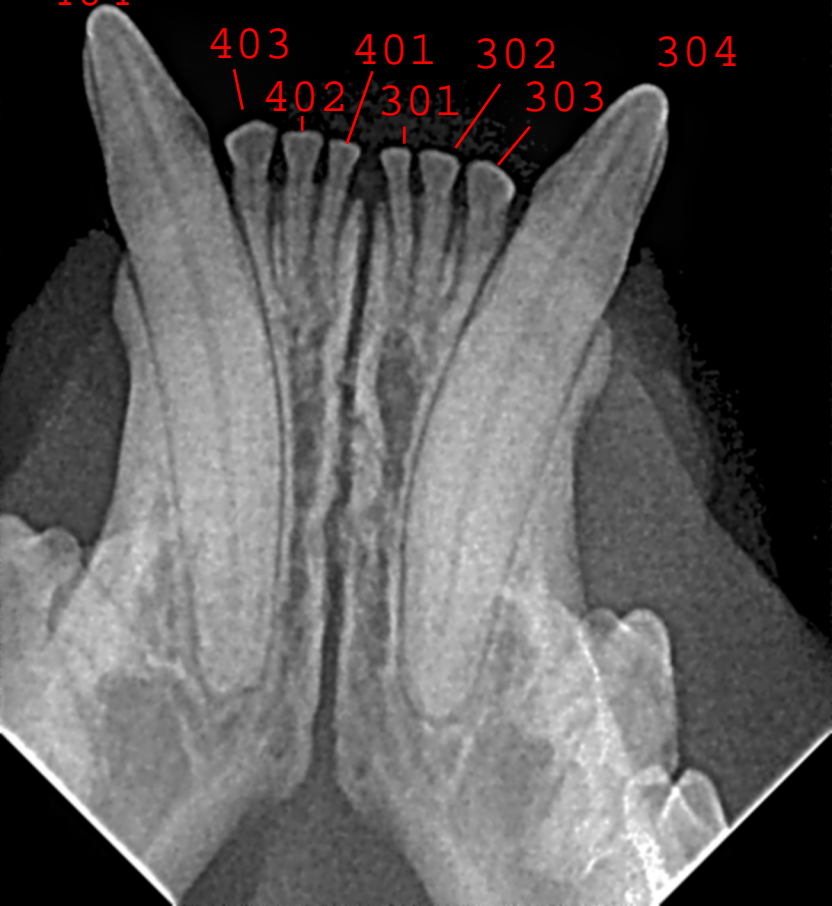
302

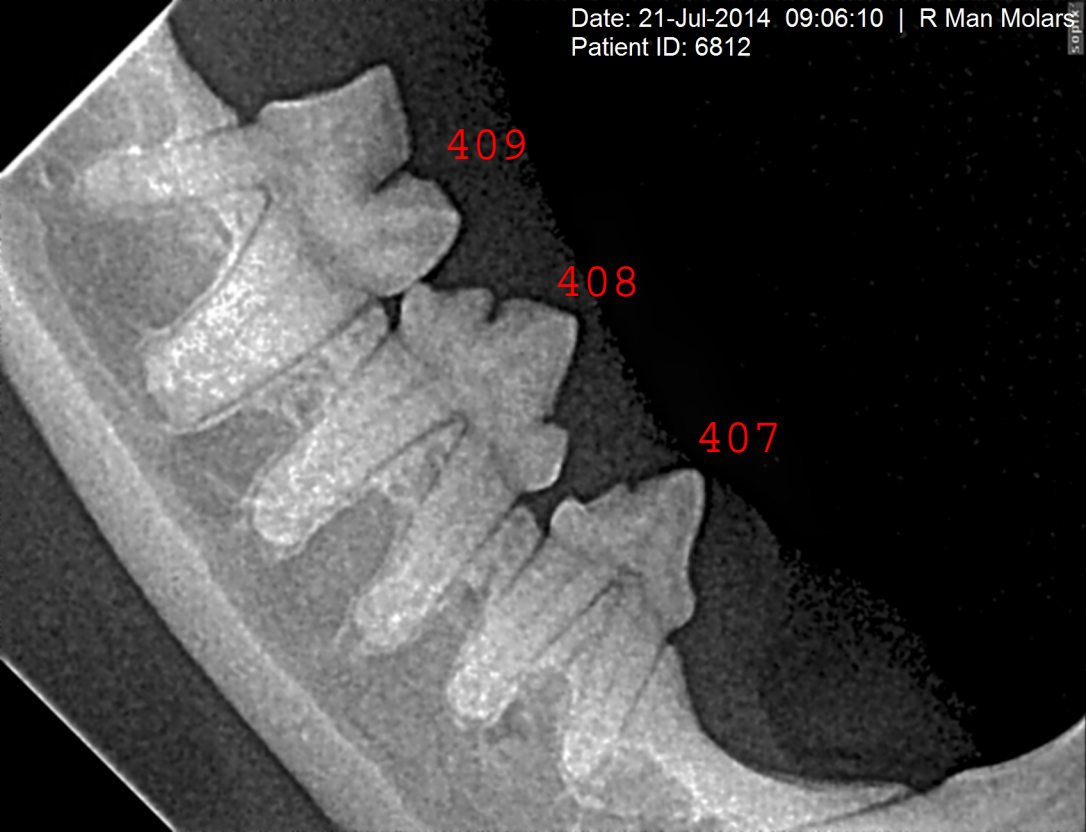
304

402

301

303





409

408

407