

HALE VETERINARY CLINIC

Fraser Hale, DVM, FAVD, DiplAVDC

BOARD-CERTIFIED
VETERINARY DENTIST™

DENTAL AND ORAL SURGERY FOR PETS SINCE 1991

PHONE
519-822-8598

FAX
519-763-6210

EMAIL
info@toothvet.ca

WEB SITE
www.toothvet.ca

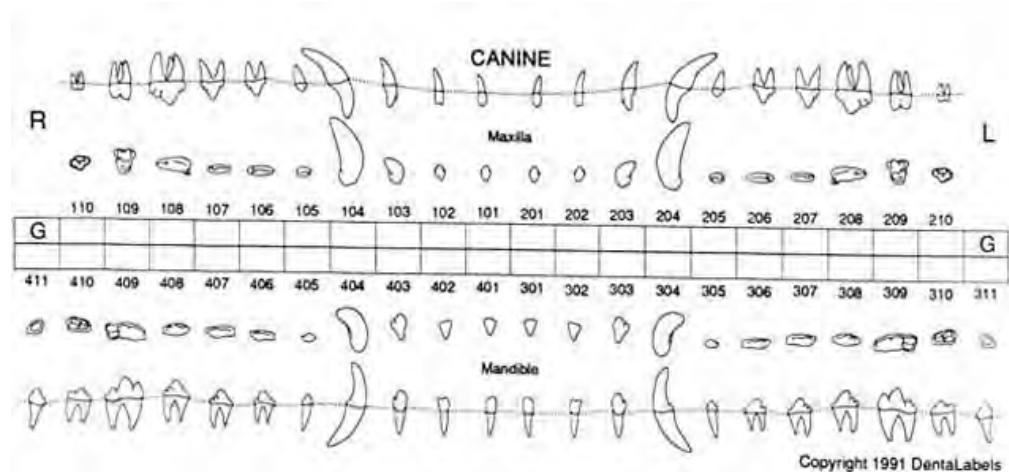
ADDRESS
159 Fife Road,
Guelph, ON N1H-7N8

OFFERING
ROUTINE AND ADVANCED
VETERINARY DENTAL SERVICES
IN THE FOLLOWING AREAS
ENDODONTICS
ORAL MEDICINE
ORAL SURGERY
ORAL & DENTAL RADIOLOGY
ORTHODONTICS
PERIODONTICS
PROSTHODONTICS
RESTORATIONS

The following images represent a typical whole-mouth intra-oral dental radiograph study of a four year old, 30 kilogram dog. It is not necessarily a "perfect" study as there are some scratches and other defects on some of the images and there is some "cone-cut" as well.

The images are presented as an example of what a pre-operative radiographic study should look like. It is also an example of a radiographically-normal set of teeth and bones in a large, young adult dog.

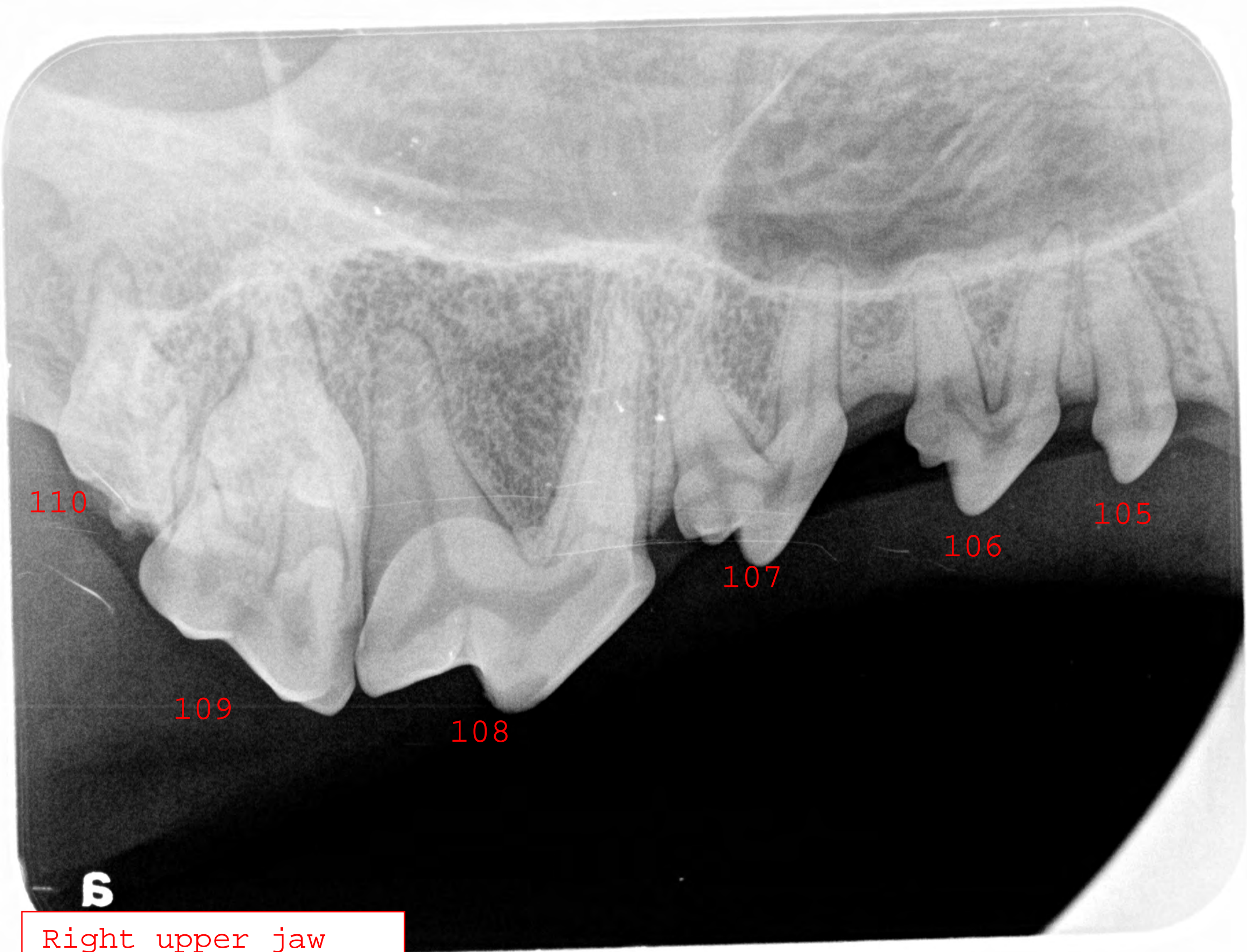
Each tooth is labeled with its Modified Triadan number.



Regards,

Fraser A. Hale, DVM, FAVD, Dip AVDC

Hale Veterinary
Professional Corporation



110

109

108

107

106

105

B

Right upper jaw

a

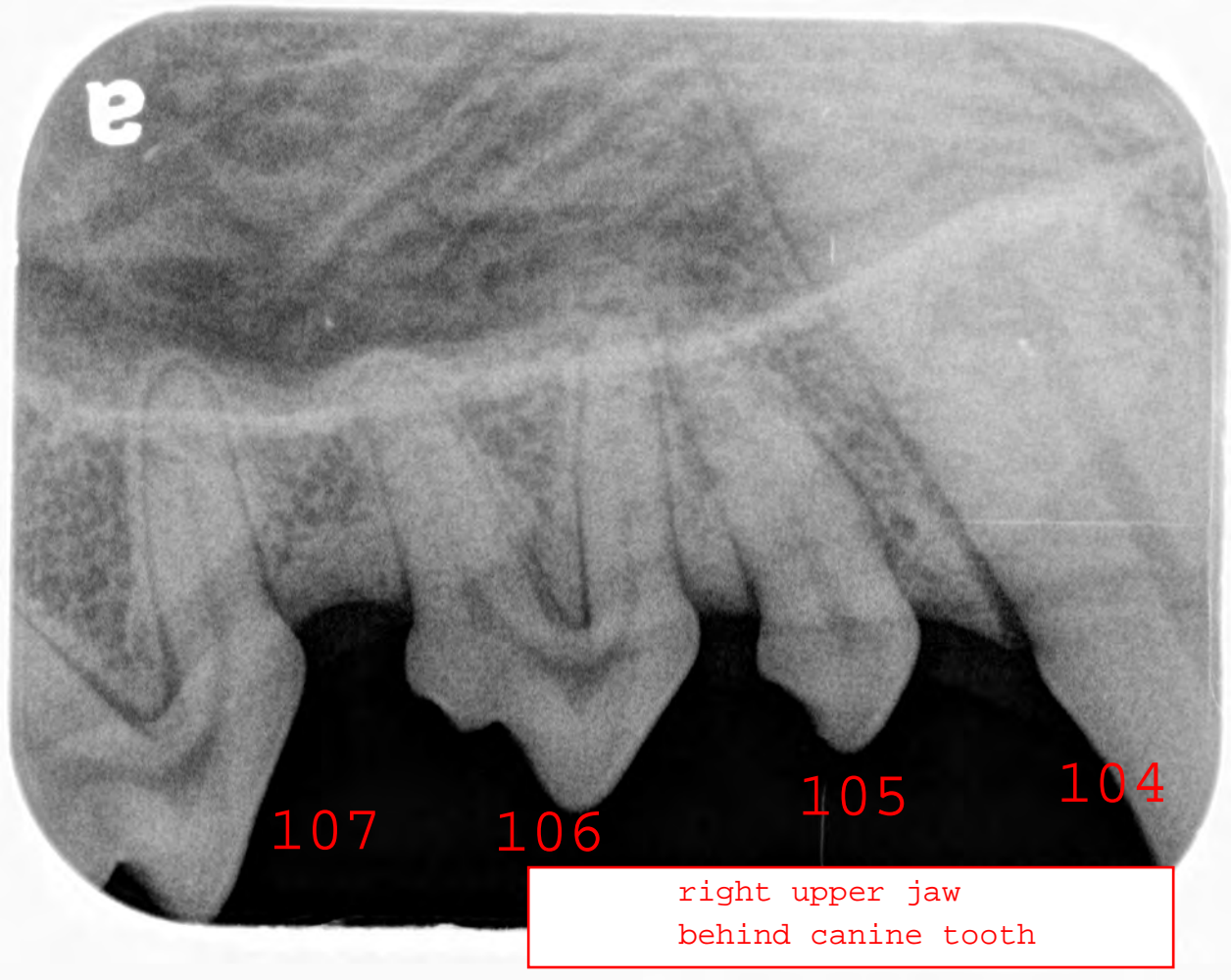
107

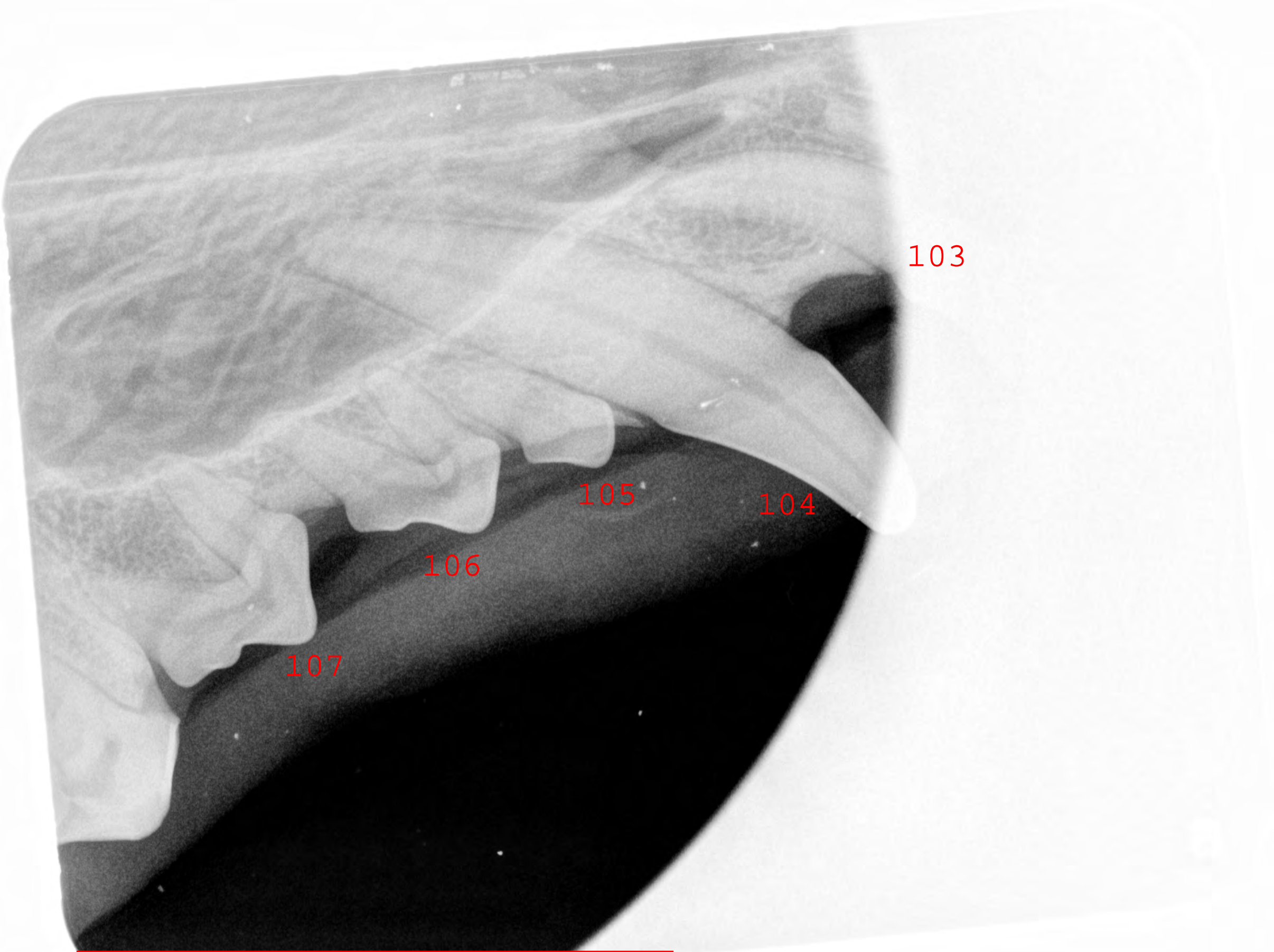
106

105

104

right upper jaw
behind canine tooth





103

105

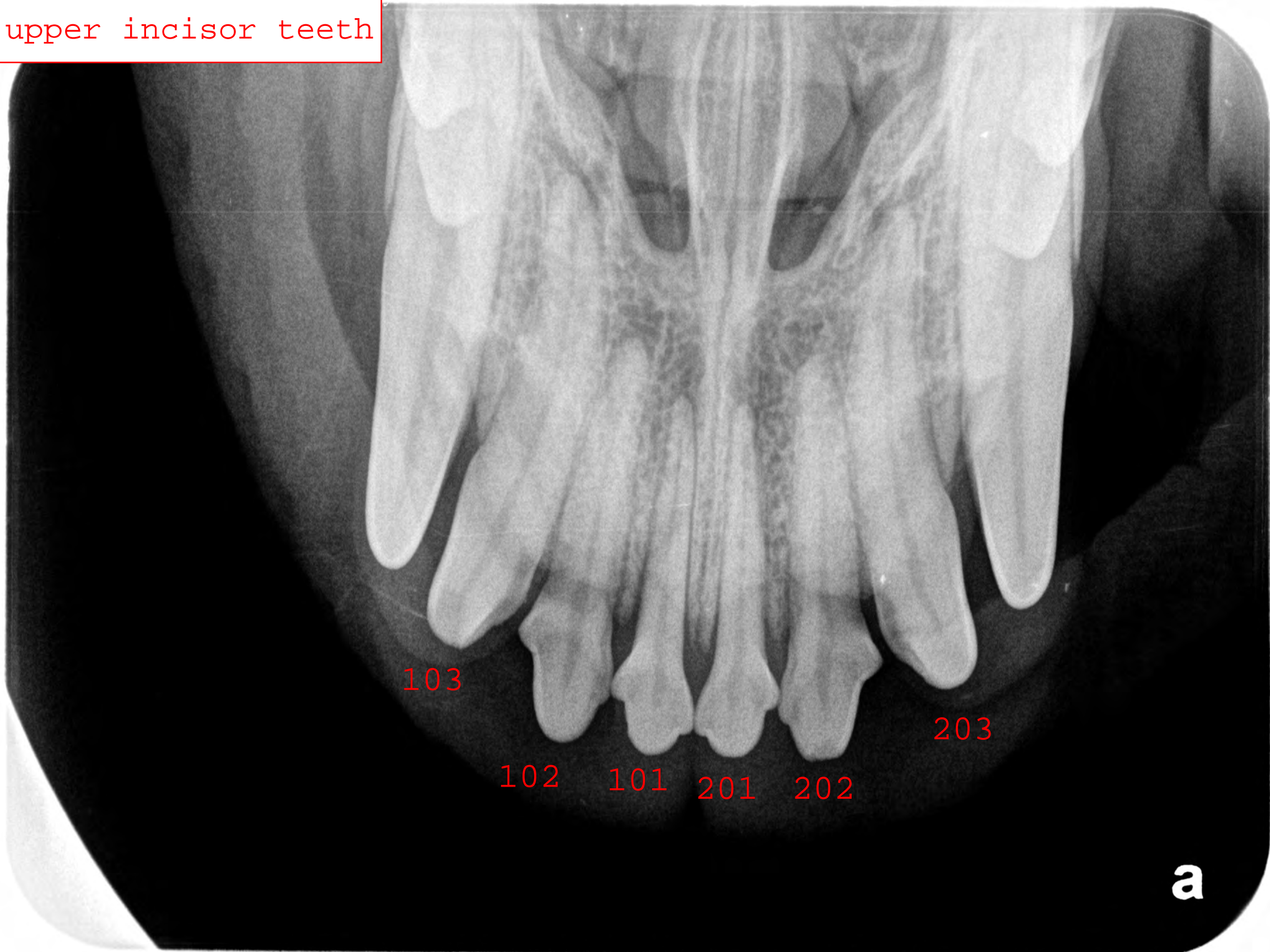
104

106

107

right upper canine tooth

upper incisor teeth



103

203

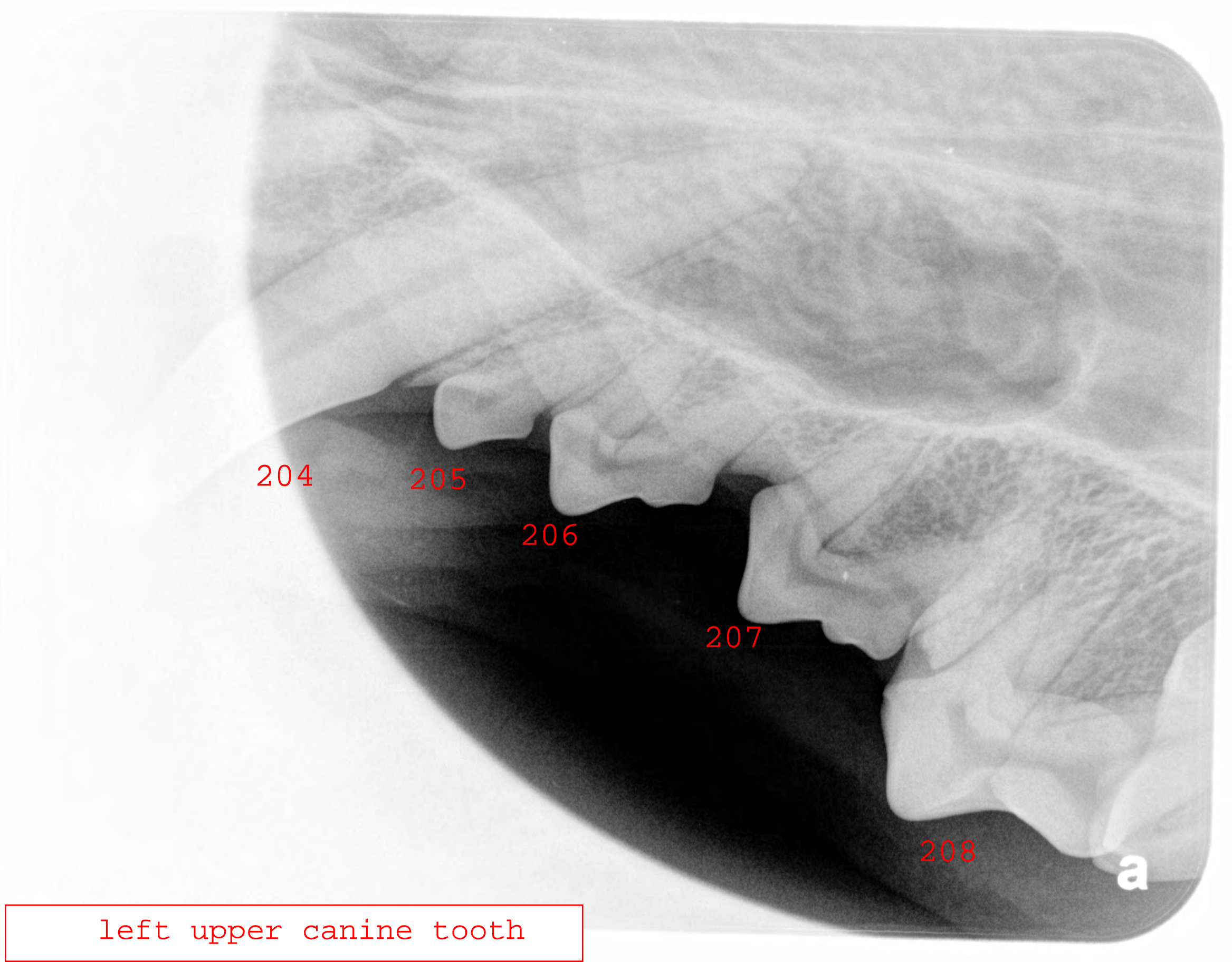
102

101

201

202

a



204

205

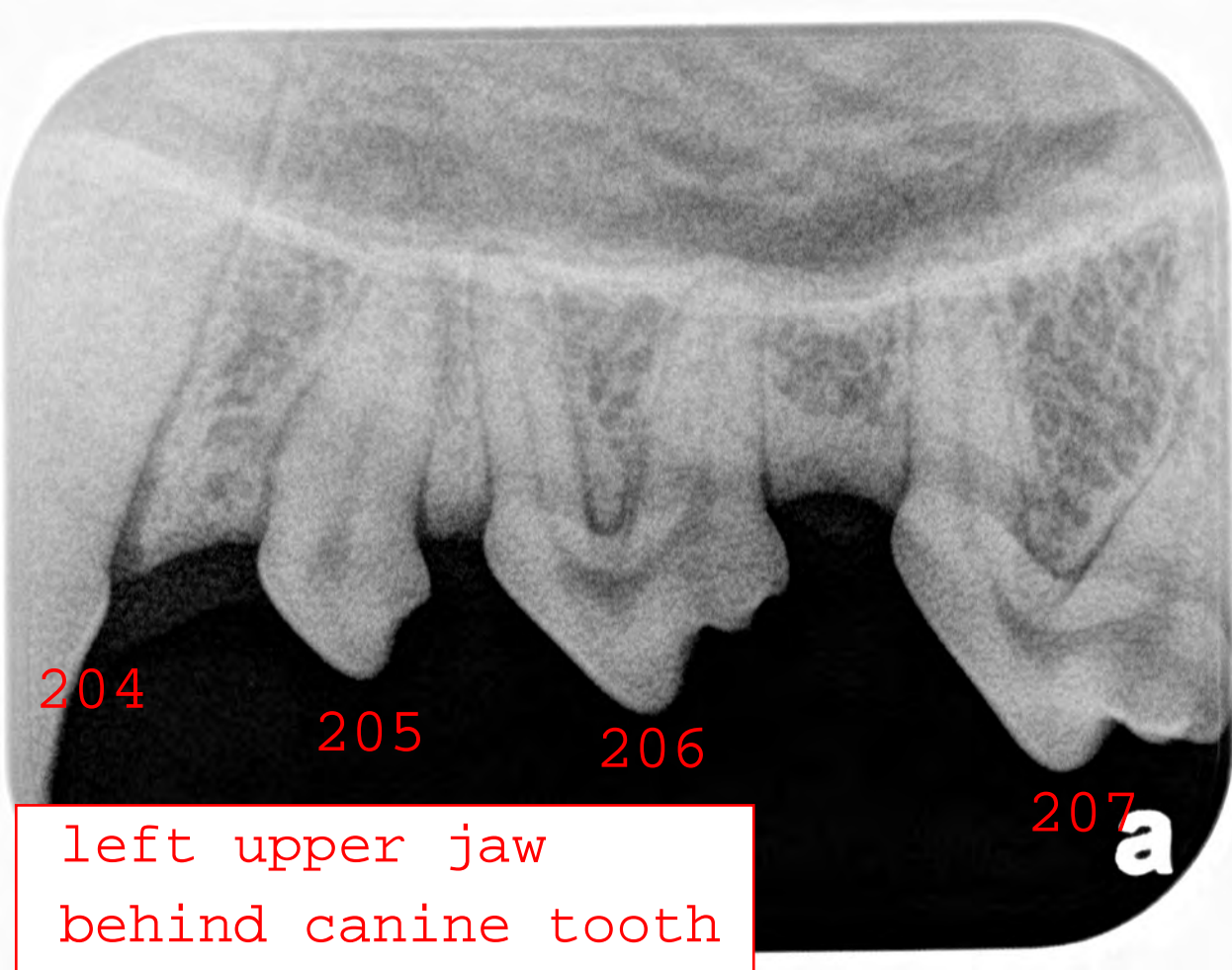
206

207

208

a

left upper canine tooth



204

205

206

207

a

left upper jaw
behind canine tooth

left upper jaw

205

206

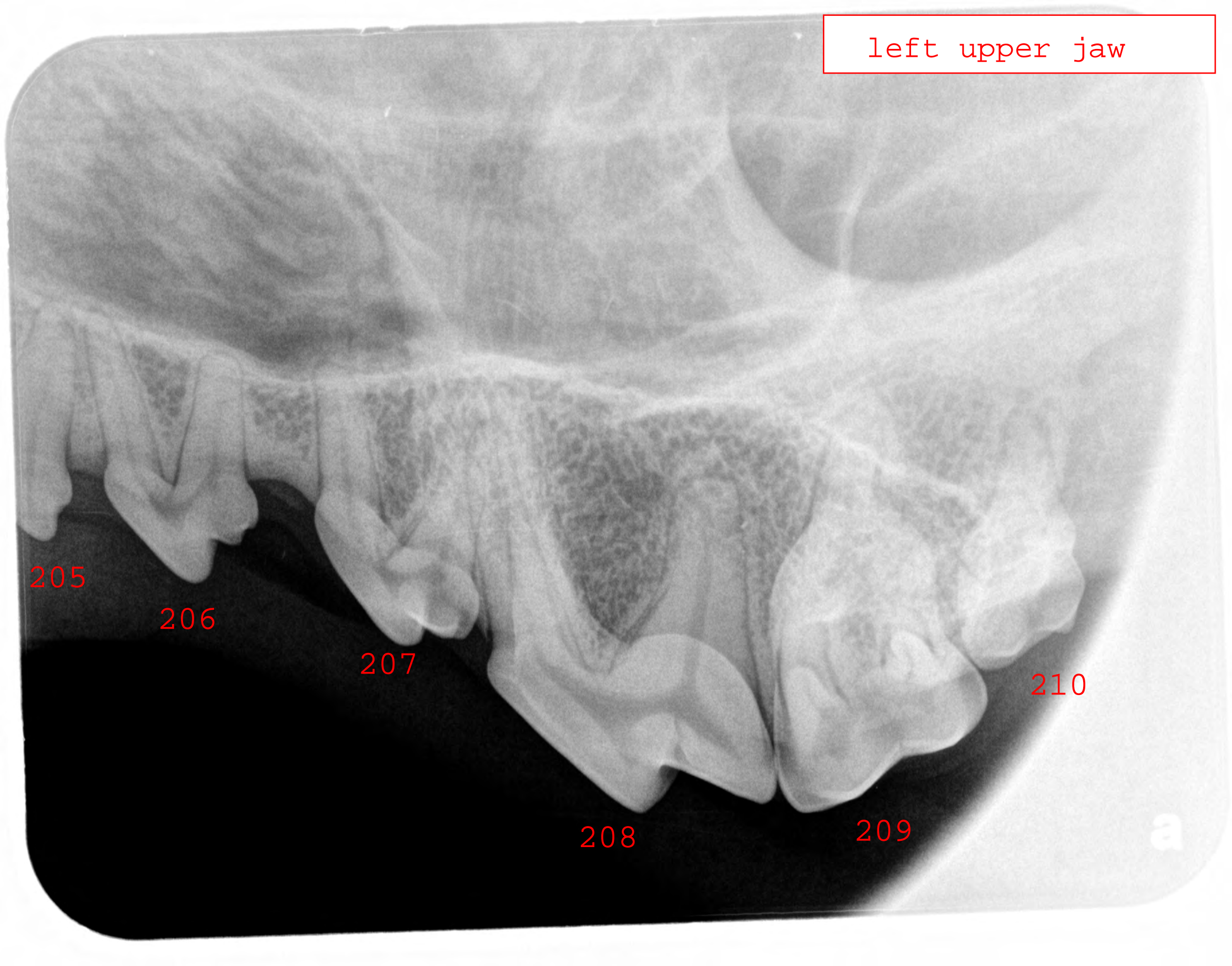
207

208

209

210

a



Right lower jaw

5546

411

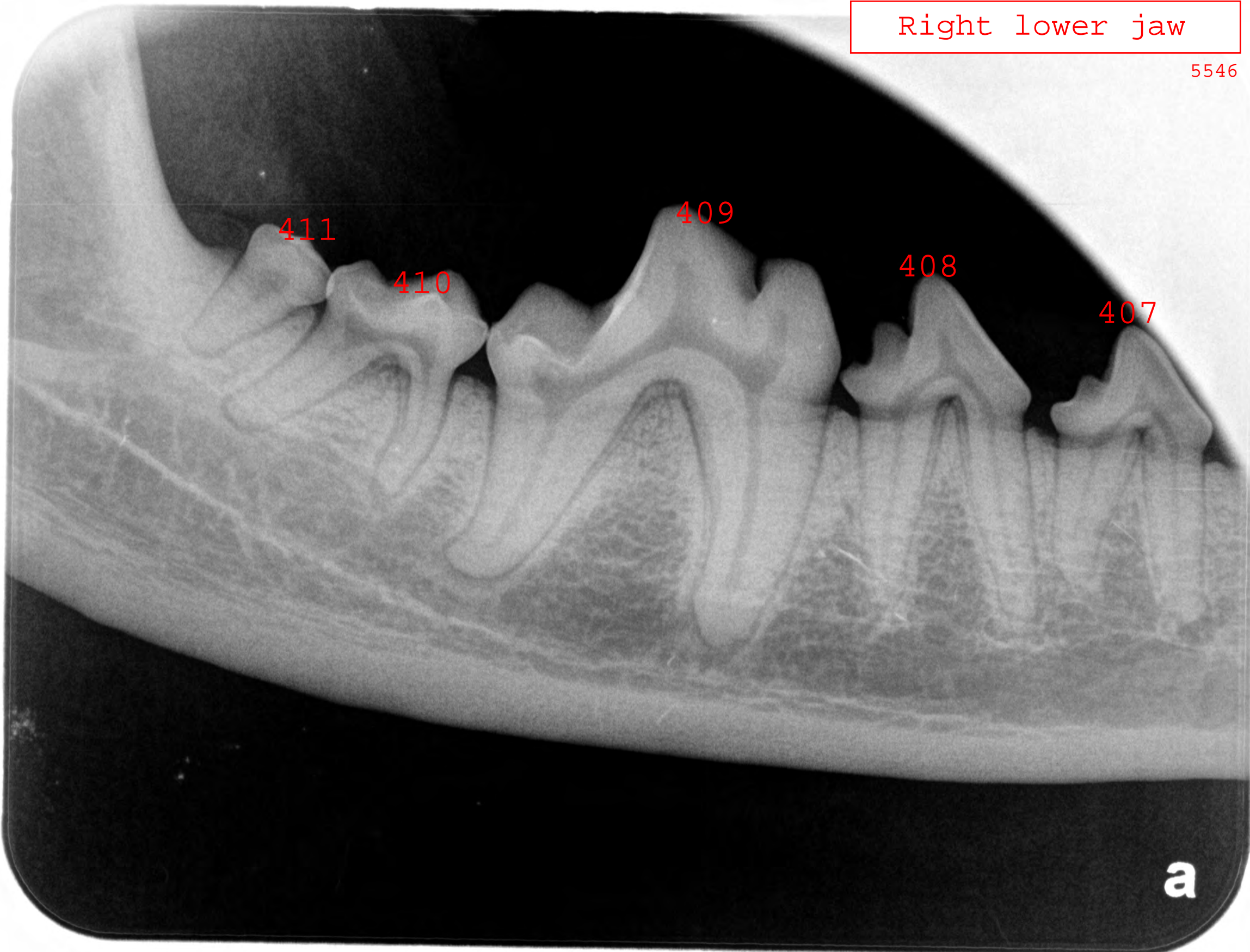
410

409

408

407

a



Right lower jaw behind canine tooth

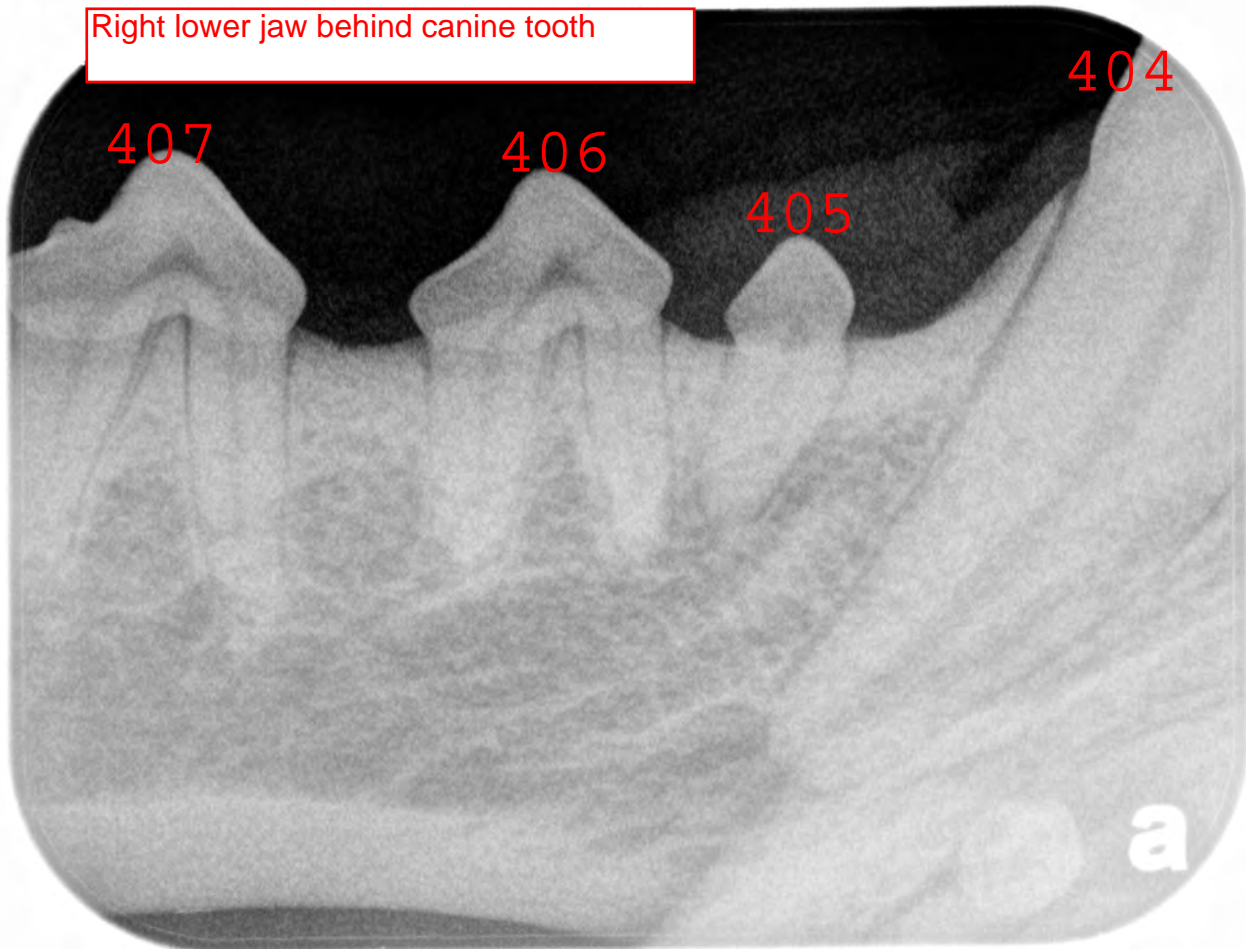
404

407

406

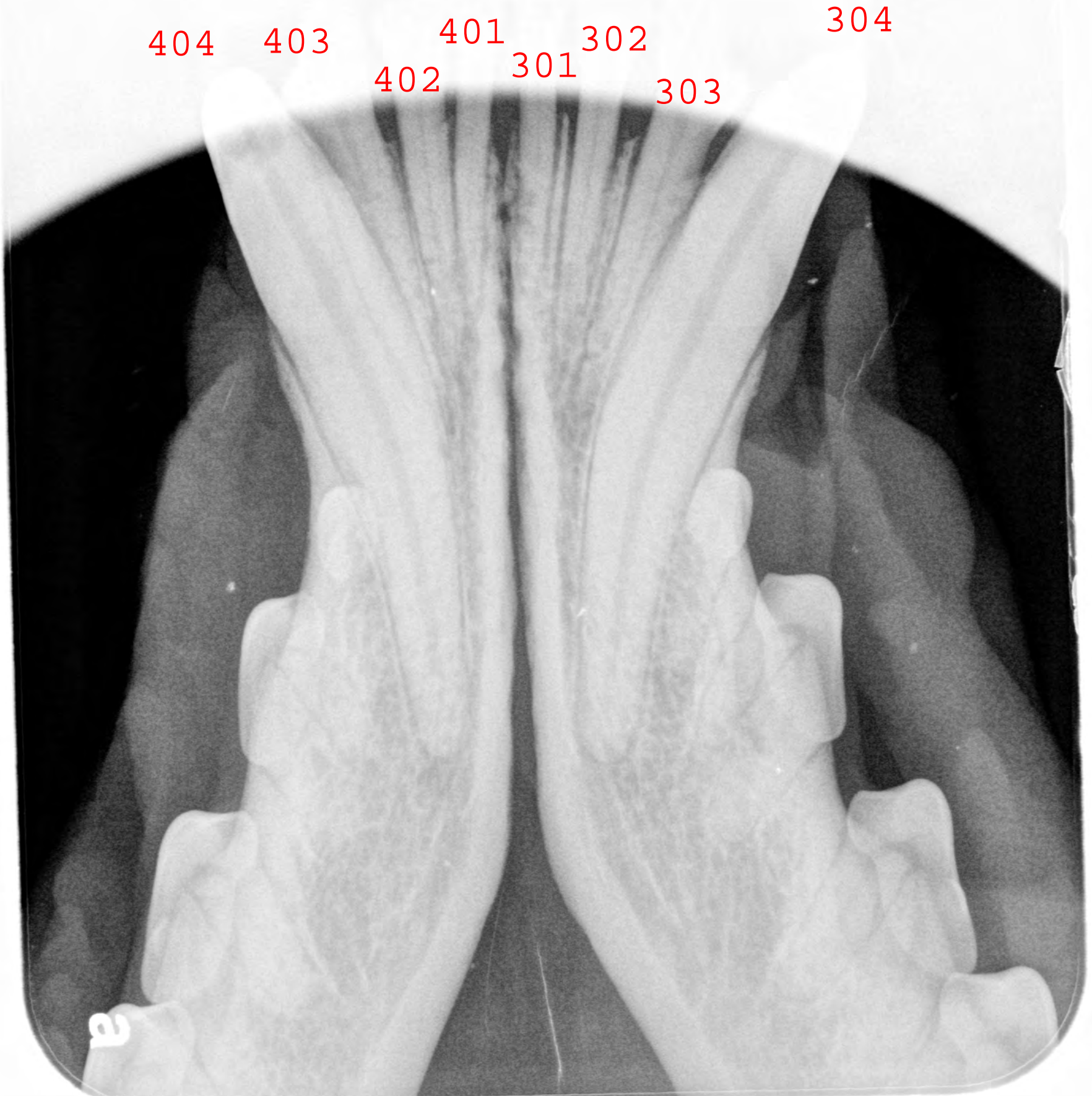
405

a



Lower canine and incisor teeth

404 403 401 302 304
402 301 303



left lower jaw behind
canine tooth

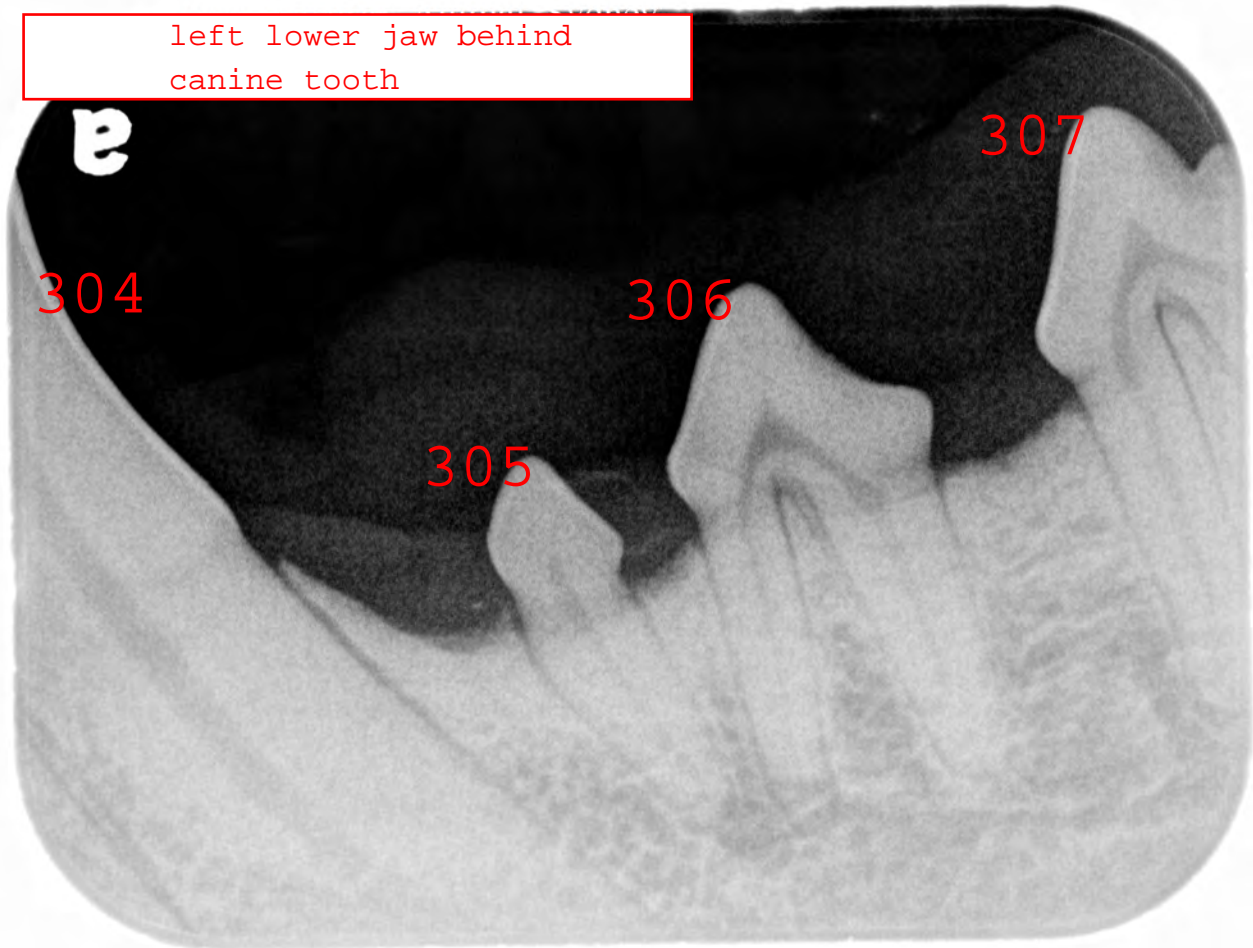
a

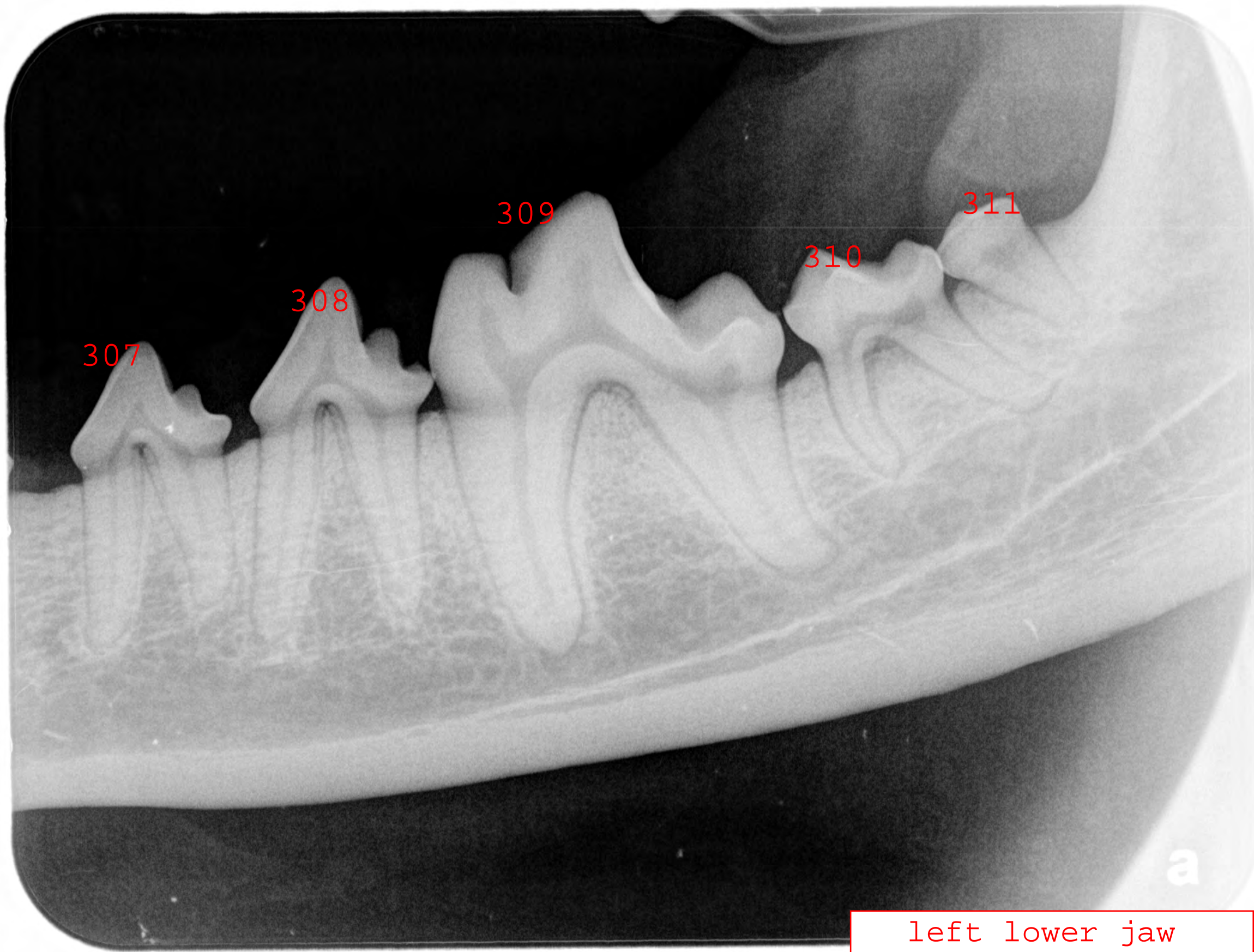
307

304

306

305





left lower jaw