

FOCUS ON: "MICRO-DOGS"

There is no definite line to define a "micro-dog", but I consider anything under 5 kg to qualify. Certainly dogs over 5 kg can have any and all of the problems I am about to discuss, but for the really little guys, I think you should assume they have these problems until you have proven otherwise.

There are seven distinct problems that should be either ruled-out or identified and addressed in micro-dogs and this should definitely be done sooner rather than later.

The problems are:

1. persistent deciduous teeth
2. impacted permanent teeth
3. missing permanent teeth
4. under-erupted teeth
5. deformed permanent teeth
6. crowded permanent teeth
7. malocclusions.

Some dogs have all of these problems, some select only a few from the menu and so the combinations and permutations are numerous. For simplicity, I will discuss each as a separate entity, though they may interact.

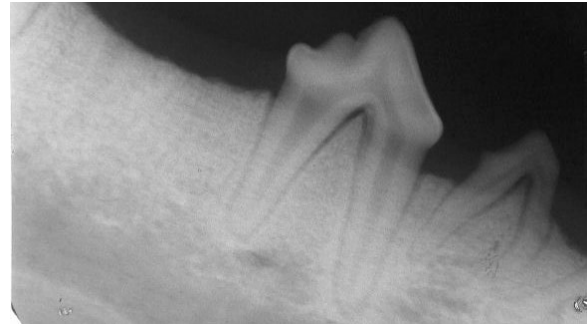
Persistent Deciduous Teeth

It seems paradoxical that the little mouths that have so little room to spare are the ones that seem most likely to hold onto the deciduous teeth as the permanent teeth erupt.

First, it must be understood that the mechanism that triggers the absorption of the deciduous tooth root allowing the crowns to exfoliate is not known. Nor is the reason for persistence of some deciduous teeth understood.

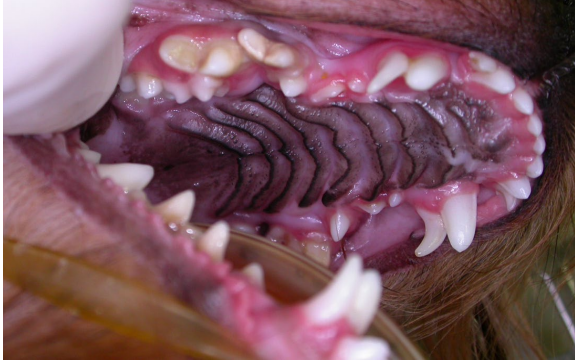It was once thought that the growth of the permanent teeth put pressure on the tissues around the deciduous roots triggering deciduous root resorption. Then a study was done in which the permanent tooth buds

were surgically removed from 8-week-old pups. The deciduous teeth fell out on schedule even though there were no permanent teeth to replace them. We have all seen dogs that were congenitally missing a permanent tooth, yet the deciduous tooth fell out anyway.

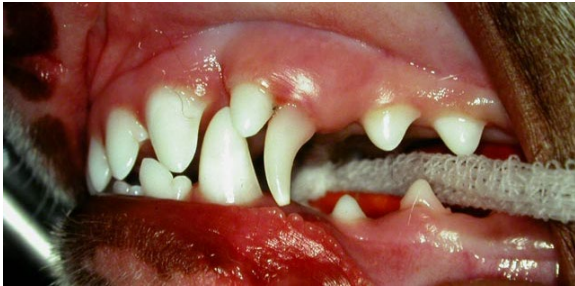

The radiograph of the right mandible of a beagle shows that the second and fourth permanent premolars are congenitally absent. The deciduous second premolar remained in place with no evidence of root resorption but the fourth deciduous premolar exfoliated normally.

Regardless of why the deciduous teeth fail to leave on schedule, when this happens, we need to intervene. The rule is that there should never be two teeth trying to occupy the space meant for one tooth. If the adult tooth has started to show itself through the gingiva, then the deciduous tooth needs to be removed to allow room for the adult to erupt into its proper position. Failure to do this in a timely manner can result in the adult tooth not erupting fully or erupting into an undesirable position.

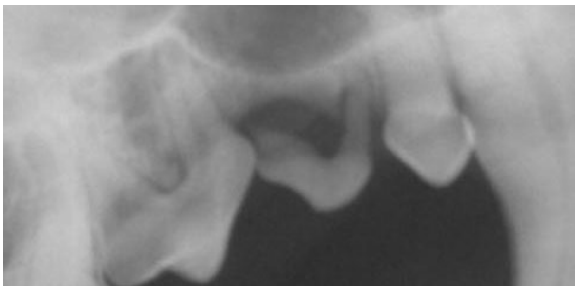

This 1.4kg Yorkie had almost all of its 28 deciduous teeth still in place at 8 months of age. This was causing displacement of many of the erupting permanent teeth.



The persistence of this maxillary canine tooth in a 6-month-old JRT was forcing the permanent canine tooth to erupt too far forward, obstructing the eruption of the lower permanent canine tooth.

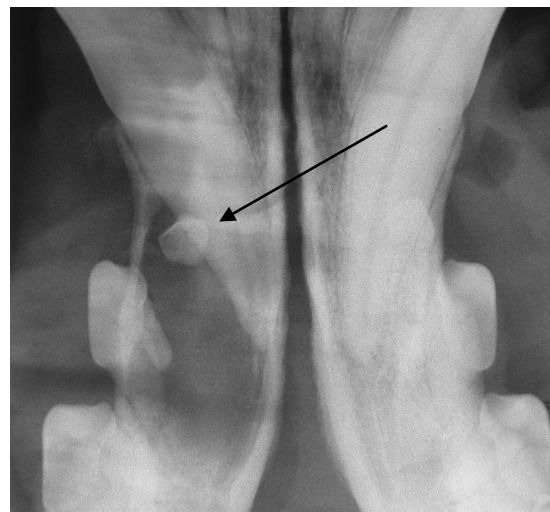
Sometimes the deciduous tooth is still in place and there is no permanent tooth trying to erupt because the permanent tooth is absent. I have found that deciduous teeth do not do well long-term in an adult mouth. Often one root resorbs but the other one holds on. In those cases, there is typically periodontal infection around the resorbed root as in the radiograph below.



Impacted Permanent Teeth

When permanent teeth are developing, there is a sac of tissue that surrounds the developing crown. This “enamel organ” is composed of an inner enamel epithelium, an outer enamel epithelium and a stellate reticulum between. The inner enamel epithelium is responsible for the mineralization of the enamel that covers the crown of the tooth. Once this is finished, the stellate reticulum atrophies and the two epithelial layers collapse onto each other to form the reduced enamel epithelium. When the tooth breaks through the gingiva into the oral cavity, most of the reduced enamel epithelium is torn away and lost, though a ring of it remains around the base of the crown to form the junctional epithelial attachment of the gingiva.

Now, when a permanent tooth fails to erupt, the reduced enamel epithelium remains intact. Often, it will then become secretory, producing a quantity of straw-coloured fluid. As the fluid accumulates, the sac expands. This is a dentigerous cyst. Left to its own, the cyst just keeps inflating and growing, while causing the destruction of the surrounding bone. Eventually the cyst breaks through the bone to cause a visible oral or facial swelling, but by this time a lot of damage has been done.



In the radiograph at the bottom-right of page 2 (of a Golden Retriever, actually), you can see the crown of an unerupted mandibular first premolar (black arrow). You can also see the very large lucent area in the mandible representing the size of the dentigerous cyst and the amount of bone destruction. This mandible is just waiting for an excuse to fracture and good luck getting it to heal.

To prevent dentigerous cyst formation, always radiograph areas of apparently missing teeth. If the permanent tooth is present but unerupted and is not likely to erupt, remove it surgically ASAP.

A longer discussion of dentigerous cysts can be found at [dentigerousecysts.pdf](#).

Missing Permanent Teeth

This is not really a problem in micro-dogs, depending on which teeth are missing. Absence of a strategically important tooth might be a concern, but there is nothing that can be done to correct the problem. On the other hand, missing some teeth can be a distinct advantage. Most of these little dogs just do not have room for all their teeth, so to be missing a few leaves room for the rest. **Just be darned sure you radiograph to ensure the tooth is missing, not hiding.** Then record it in the permanent record as being radiographically confirmed to be absent.

For some breeds, missing several teeth may be a problem if showing and breeding were part of the plan.

Under-erupted Permanent Teeth

Sometimes adult teeth are prevented for erupting fully due to crowding issues. Sometimes they fail to erupt for no particular reason. Under-eruption of the canine teeth

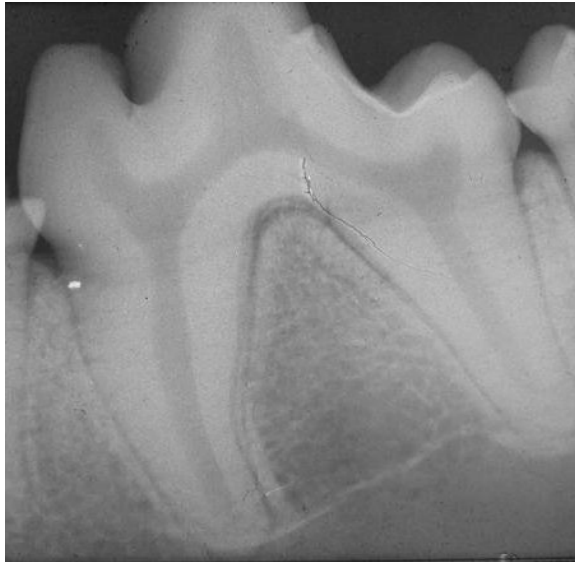
seems to be particularly common in shih tzus, Boston terriers any pugs (in my experience). As this is a complex issue, I have a sparate paper that discusses it in detail. Here it is - [pericoronitis.pdf](#).

Deformed Permanent Teeth

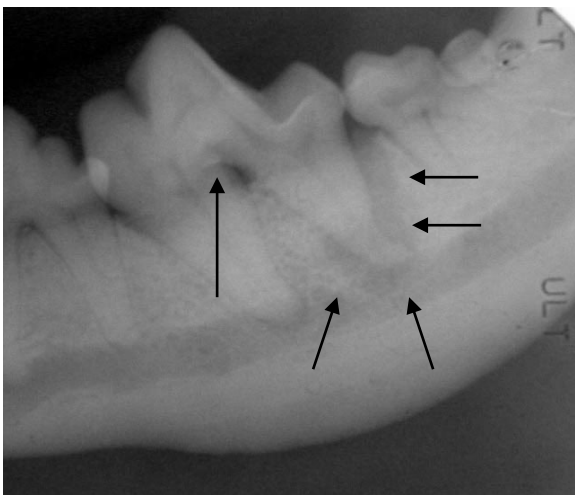
Any tooth can be deformed and in a variety of ways, but there is one form of deformity to which micro-dogs seem particularly prone. At present, we are just calling these dilacerated (bent) mandibular first molars.

Normally the roots of the mandibular first molar are divergent as in the radiograph top right. In the normal tooth, the only way into or out of the endodontic chamber is through the apical delta (a collection of tiny channels at the tip of the roots) [see [endo.pdf](#) for more detail].

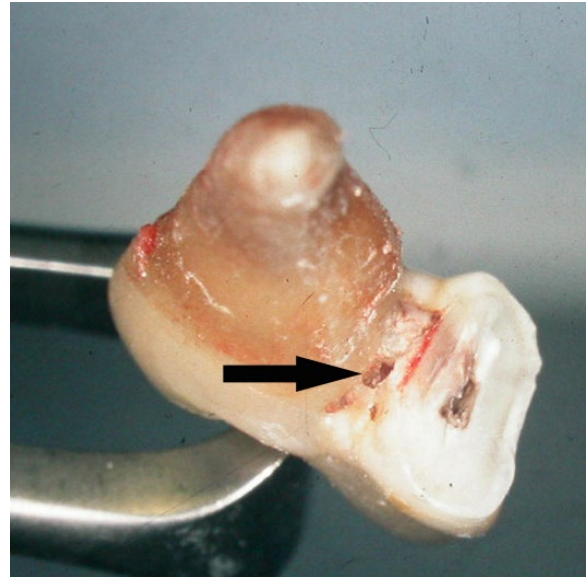
With dilacerated mandibular first molars, the roots are more parallel or convergent (sometimes the tips even cross over each other). More importantly, there are typically one or more openings directly into the pulp chamber located near the base of the crown of the tooth or in the furcation. This allows oral bacteria to gain access to the pulp, causing a septic pulp necrosis. The infection then oozes out through the apical deltas to cause infection in the surrounding bone.



The radiograph (bottom right of page 3) is of a normal left mandibular first molar in a dog.



The roots of this (above) left mandibular molar are parallel. There is a large lucent area around the apex of the distal root and running up the distal root to the top of the socket. This lucency is the result of osteomyelitis secondary to endodontic infection. The bacteria got into the pulp chamber through a small hole in the furcation as seen in the photograph following. This infection had chronically weakened the area around the distal root so there was a compensatory callus along the ventral cortex of the mandible to prevent pathological fracture.

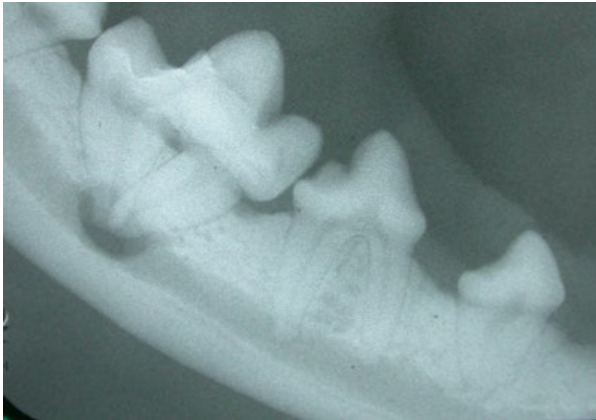
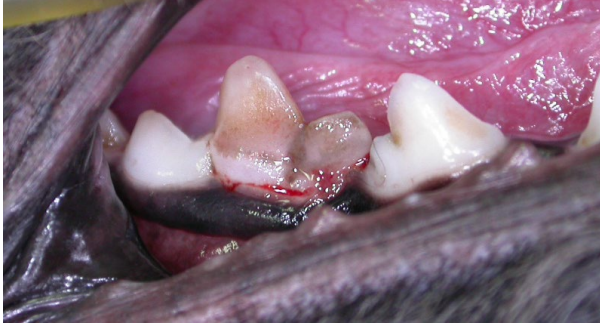
The photo at the bottom of the left column is of part of this molar following extraction. The mesial root is to the left of the picture and the distal root is not present, having been sectioned from the tooth and removed separately. The arrow points to the abnormal opening into the pulp chamber in the furcation of this tooth.

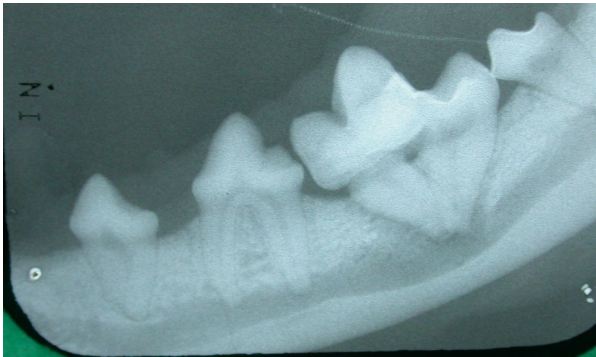
In most of the cases I have seen either personally or reported by others, the condition is bilaterally symmetrical. Therefore, if you find it on one side expect to find it on the other and look for it. It is also most common in very small dogs, but the molar pictured above was from quite a large Pomeranian and it was unilateral, and I had a bilateral case in a Cocker Spaniel and a large Lab mix.

Here are some more typical cases.

This was a 2 kg tea cup poodle. The mandibular molars looked a bit odd clinically.

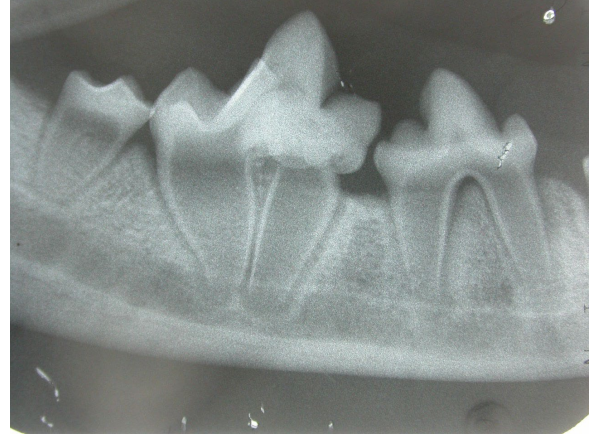

The radiograph of that right first molar showed roots that converged to the point of touching and a beautiful hole right through the mandible caused by the chronic endodontic disease.

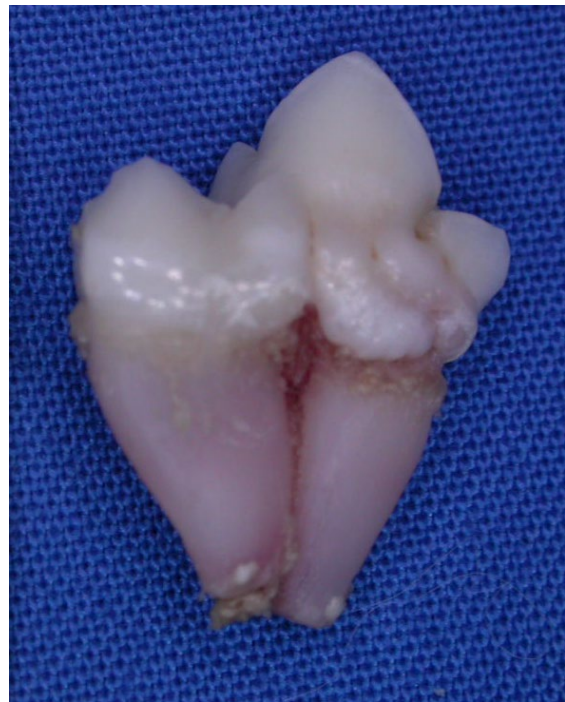

The lower left first molar was similarly deformed, though the radiographic evidence of endodontic disease was less dramatic. Both of these molars required extraction.

Here is another micro-poodle but at a much younger age. This tooth was also extracted...



Compare that radiograph to the normal one at the beginning of this section. The tooth looked like this after extraction.



He was bilaterally affected.

I have never seen one of these dilacerated molars that did not require extraction. So, look for them and when you find them, get them out.

Crowded Permanent Teeth

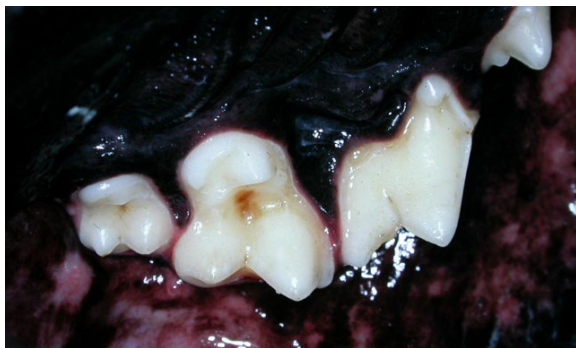Micro-dogs have micro heads and micro mouths. Unfortunately, they often have macro teeth. It turns out that tooth size is very resistant to breeding influences and so

on a pound-for-pound basis, little dogs have very big teeth compared to big dogs. If all the teeth (or even most of them) develop, there is rarely room for them to all fit in the mouth properly. This can cause various occlusal problems (see next section) but here I want to discuss the periodontal ramification.

It would be good if you review this paper first - [PerioAnat&Physio.pdf](#).

An intact collar of attached gingiva around the entire circumference of the tooth is the barrier to periodontal disease. When teeth are severely crowded, there is no room for gingiva or even alveolar bone between the teeth and so periodontal disease starts early and progresses rapidly.

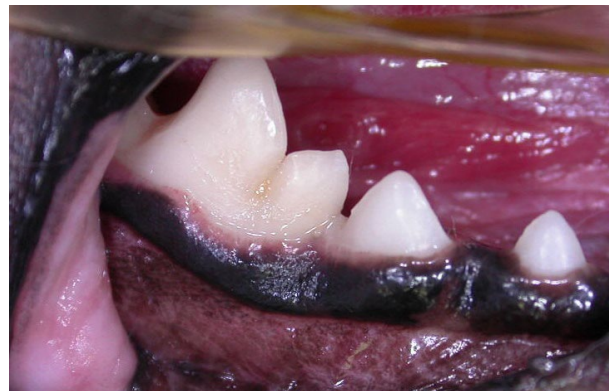
One common place for this is between the maxillary molars. In micro-dogs, the roots of the second maxillary molar may only be 2 to 4 millimeters long and so a periodontal pocket of 2 millimeters constitutes 50%-100% attachment loss which is end-stage periodontal disease and indication for extraction. In the photo from a large dog, we see nice spacing between the maxillary molars with good gingiva filling this space.



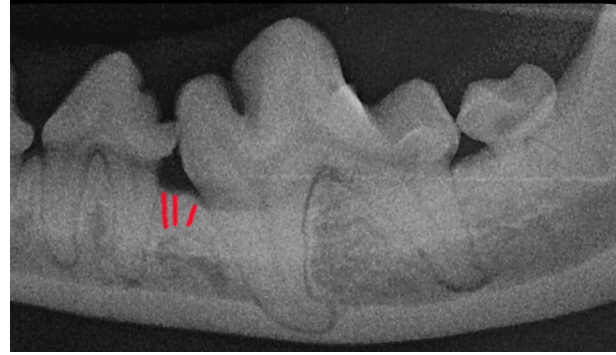
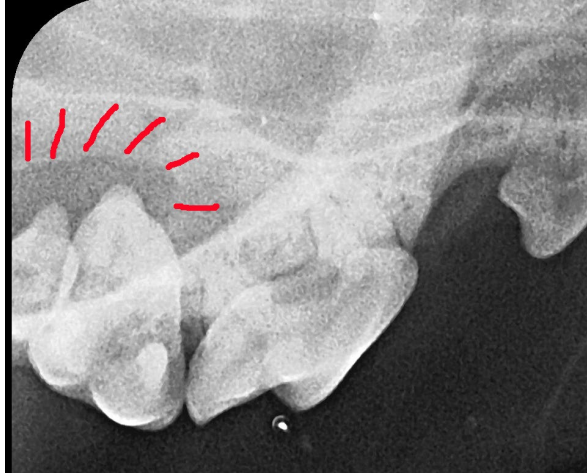Micro-dogs rarely have this. They have the second molar jammed so tight against the back of the first that there is no gingiva and no bone between them. My approach is to sacrifice the second molar and suture the gingiva around the back of the first molar. This gives the larger and more important first molar a fighting chance. Failure to do

this means (in most cases) early onset of periodontal disease in an area that is virtually impossible to reach for proper treatment and home care, so you end up losing both teeth. Here is a report of just such a situation.

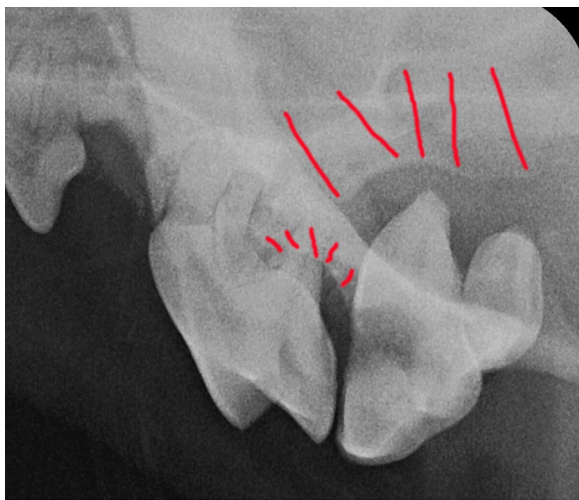
I saw an eight-month-old micro-poodle (1.6kg) in August of 2004 to remove some retained primary canine teeth. At that time I also did some selective extractions to reduce crowding and improve the periodontal future for the teeth left in place. My discharge notes to the owner and letter to the referring veterinarian both stated plainly that this dog would be very prone to periodontal disease. I recommended t/d™, daily tooth brushing and annual [COHATs](#). Well, this little un-neutered male refuses to allow home care. They have been feeding t/d™ but he was not presented for his first dental treatment until this fall (three years later than my recommendation). When the rDVM removed calculus from the crowns, it was apparent that more than a cleaning was needed and so the dog was sent my way again. Because he had just had his teeth cleaned, the clinical photo looks pretty good.



The radiographs, however, tell a different story:



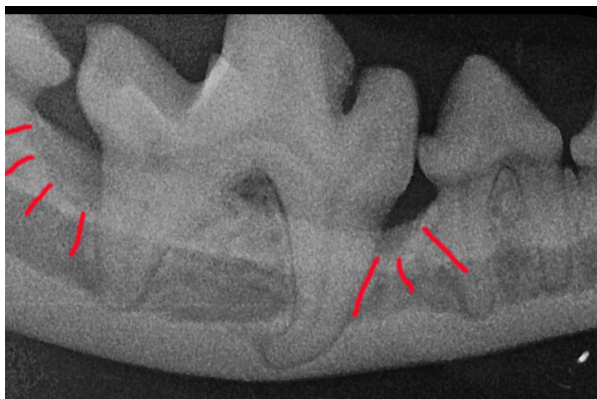
There are deep infra-bony pockets mesial and distal to the right lower first molar (the area that looks good in the photo) and a suggestion that the same thing is about to get started mesial to the left lower first molar.



There is complete loss of the bone around the upper first and second molars on both sides as well as end-stage periodontal disease along the distal root of the left upper fourth premolar tooth.

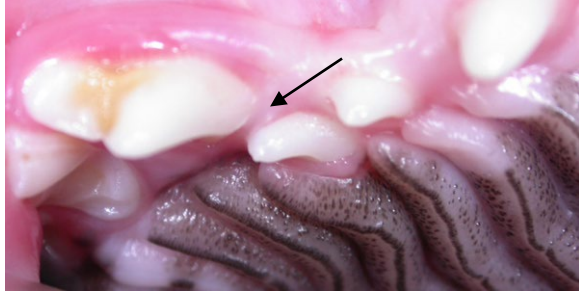
In the end, I extracted a total of eleven teeth that were well beyond salvage. I did periodontal surgery with placement of a synthetic bone graft around the lower right first molar as well as some open root planing in a few other areas. Now we have to see how this patient can respond to that treatment.

Another serious crowding concern is between the maxillary third and fourth premolars. Recall that the upper fourth premolar has three roots – one distal, one mesiobuccal and one mesiopalatal. Where two roots come together to join the crown is a furcation, so there is a mesial furcation between the mesiobuccal and mesiopalatal roots of the fourth upper premolar.

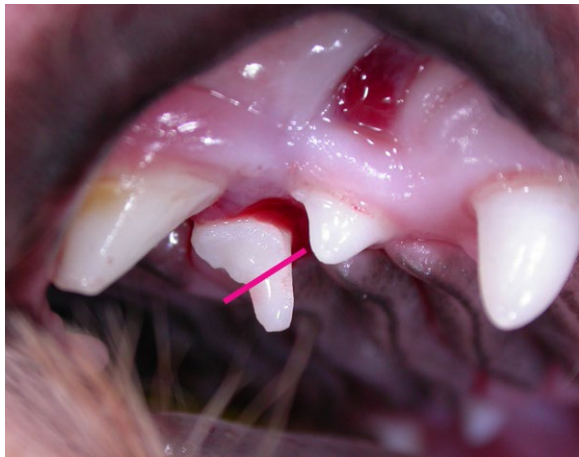

Recall also that gingiva and periodontal ligament will attach only to cementum and alveolar bone – they will never attach to enamel.

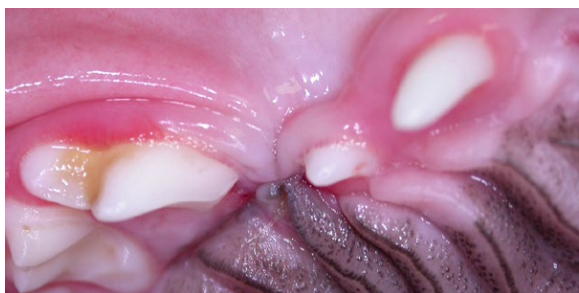If the third and fourth premolars are crowded together, the distal shoulder of the crown of the third can get trapped in the mesial furcation of the fourth. This traps a lot of the enamel-covered crown below the gum line and in the periodontal space of the mesial roots of the important fourth premolar tooth.



In the photo above, it appears as if there is plenty of room between the third and fourth premolar and gingiva in the inter-dental space (arrow). However, after taking out the mesial root of the third premolar I elevated the distal root and paused in the extraction to take this picture.



The portion of the crown to the upper-left of the pink line was all trapped subgingivally in the mesial furcation of the fourth premolar and was a free-ride for bacteria into this space. Selective extraction of the third premolar allowed me to close thus.

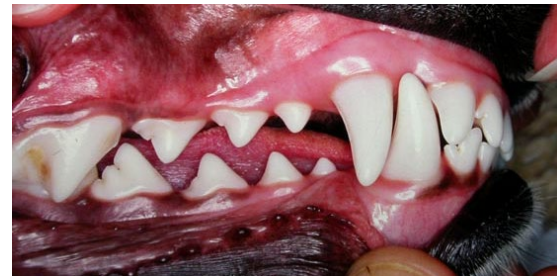

Now the fourth premolar has a future.

The third common place for me to selectively extract to alleviate crowding and to improve the periodontal prognosis for the remaining teeth is the mandibular corner incisors. Crowding between the corner incisor and the canine tooth puts both at risk. Removal of the incisor improves the outlook for the much more important canine tooth.

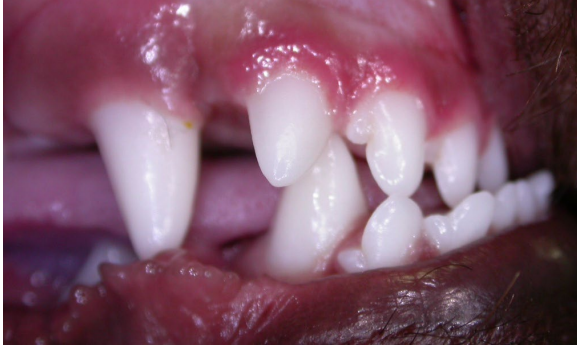Malocclusions

Some breeds have malocclusion as a breed standard. Shih Tzus are designed to have a Class III malocclusion (upper jaw too short compared to the lower). Though this is normal for the breed, it is not healthy or comfortable in many cases (see [Focus On Boxers.pdf](#) for an article that discusses Class III malocclusion). Basically any malocclusion that causes abnormal tooth-to-tooth or tooth-to-soft tissue contact needs to be alleviated.



In a dog's mouth, the teeth are not supposed to touch soft tissue at all, so any tooth-to-soft tissue contact is abnormal. The only place there is supposed to be any tooth-to-tooth contact is between the upper and lower molars. Any other tooth-to-tooth contact is abnormal.

Some malocclusions result in teeth crashing into each other leading to abrasive wear and/or traumatic pulp necrosis. Some malocclusions result in some teeth blocking the eruption path of other teeth. Some malocclusions result in teeth causing serious (and painful) trauma to the oral soft tissues.



boxers should have whole-mouth radiographs as they often have extra, unerupted teeth, leading to dentigerous cyst formation.

This toy poodle has a Class III malocclusion in which the upper corner incisors are obstructing the eruption of the lower canines and the other upper incisors are going to contact and traumatize the lower incisors and/or the floor of the mouth. All six upper incisors need to be extracted.

No dog needs a perfect bite but every dog deserves a comfortable one. If achieving this objective means selective extraction, then that is a medically appropriate procedure.

Conclusion

When I sit down to write one of these newsletters, I always wonder how I am going to fill eight pages. Then I get started and realize that eight pages is only enough for a brief introduction, a teaser, a tiny sampling of what I see. The “take home” message from this article is that small dogs are particularly prone to a number of serious dental and oral abnormalities. They need to be carefully assessed and identified issues addressed before they become much more serious. As always, intra-oral dental radiographs are an essential component of procedure.

The Micro-dog work-up should be done and problems treated at 6 to 7 months of age for maximum benefit.

Finally, regardless of size EVERY brachycephalic dog needs the Micro-Dog approach as that short maxilla will result in crowding and malocclusions and ALL