

MALOCCLUSIONS

WHAT TO DO ABOUT THEM, WHEN AND WHY

In this paper I will discuss some of the more common malocclusions affecting dogs (and less frequently, cats), why they are of significance, what to do about them, when to do it and why. There is no way I will be able to cover every scenario, but I hope this paper will help you with the common ones and may give you the tools to figure out the odd-ball cases too.

Dogs and cats do not need perfect bites, but they deserve comfortable bites. The things that should always trigger intervention are abnormal tooth-to-tooth and tooth-to-soft tissue contacts.

My hope had been to keep this paper short and to the point. As I went through the process, however, I realized that a four-page bulletin would have raised more questions than it answered and realizing that a little knowledge can be a dangerous thing, I decided I had to dive in a bit deeper. Even so, this should be considered a very brief introduction to the various subjects covered.

In some instances, I will mention a subject upon which I have already written and so there are active hyperlinks that will take you to those papers for more detail on these issues.

Malocclusions of the Primary Teeth

We are going to start with puppies and kittens and the occlusal problems you might find during the first few veterinary visits. I am talking about malocclusions involving the primary teeth. But first, some background information.

Primary Dental Formulae and Anatomy

The primary dental formula in dogs is $2 \times i3/3, c1/1, p3/3$ which means that on each side of the head, there are three primary incisors top and bottom, one primary canine top and bottom and three premolars top and bottom. There are no primary molars ever. Neither are there ever any primary 1st premolars. This first primary tooth behind the canine is the 2nd premolar in each quadrant, then the 3rd and then the 4th.

In cats, the primary formula is $2 \times i3/3, c1/1, p3/2$ meaning each side of the mouth has three primary incisors, one primary canine top and bottom, three premolars in the maxilla and 2 premolars in the mandible. The upper premolars are considered the 2nd, 3rd and 4th and the mandibular ones are considered the 3rd and 4th primary premolars (so as well as having no primary molars and no primary 1st premolars, cats are also missing the mandibular primary 2nd premolars).

Confusingly, the 3rd primary premolar in each quadrant has the structural anatomy and the function of the adult 4th premolar and the 4th primary premolars have the form and function of the adult 1st molars. Here is a chart of the primary dentition in dogs: [Dog Deciduous Chart.pdf](#).

And here is a primary chart for cats: [Cat Deciduous Chart.pdf](#).

Note that when using the modified Triadan numbering system for the primary teeth, the right maxilla is the 500 series, left maxilla is the 600 series, the left mandible is the 700 series and the right mandible is the 800 series.

From the rest of this section, when I am referring to any tooth/teeth, unless stated otherwise, I will be referring to the primary tooth/teeth.

Classification of Malocclusions

We must abandon the use of the terms overbite or underbite. They are as confusing as the date 05-07-09 (is that May 7th or July 5th of 2009 or maybe even July 9th of 2005?). So, let us use Angle's classifications which are as follows:

Normal Occlusion: proper craniofacial development with appropriate jaw-length relationships (upper and lower jaws proper lengths in their own right and in relation to each other), proper jaw width relationship and all teeth present and in their proper position/alignment.

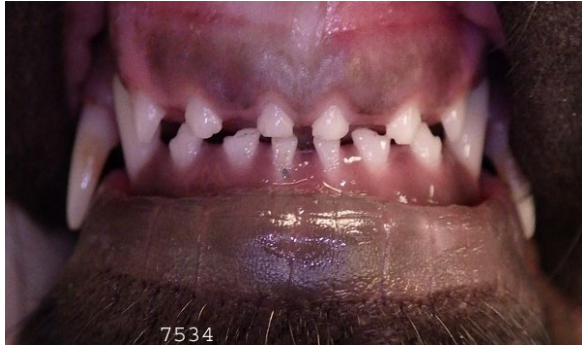

Figure 1

Figure 1 shows some features of a normal puppy mouth. We see six upper and six lower incisors. The maxillary midline is directly above the mandibular midline and there is good symmetry right-to-left. The lower incisors are just behind the upper (scissors occlusion). The width of the mandibles is also appropriate compared to the maxilla.

Figure 2 is a side view of the same pup (just happens to be a 13-week-old Lab). It shows how the lower canine tooth is centred in the space between the upper third incisor and canine teeth and is tipped labially at enough of an angle that it is not in direct contact with the maxillary soft tissue. We can also see how the lower incisors are tucked up right tight behind the upper incisors.

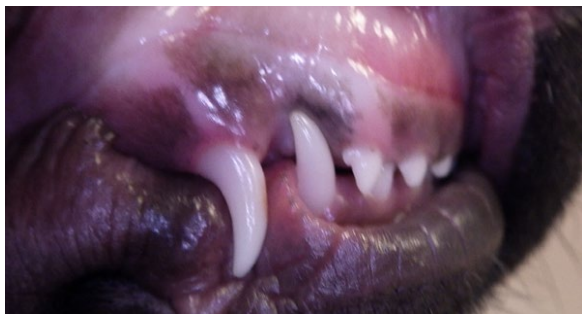


Figure 2

I do not seem to have any photos showing the relationship of the primary premolars but they are relatively small and well-spaced apart. I do not recall seeing clinically relevant occlusal issues with the primary premolars in the past.

Class 1 Malocclusion: normal craniofacial anatomy but one or more teeth out of place within a normal skeletal framework. This is considered a dental malocclusion as it is the tooth (teeth) that is at fault. In Figure 3, the jaw-length relationship is great (lower incisors just behind the upper incisors and lower canine in proper location in the rostral-caudal dimension). However, that lower primary canine tooth is lingually displaced (linguoversion aka “base-narrow”) and so is in traumatic contact with the maxillary tissues (note the inflammation – ouch).

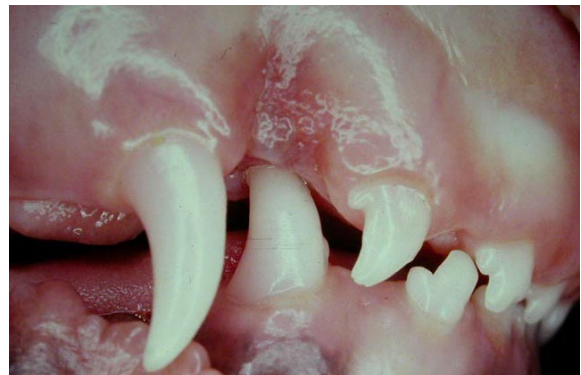

Figure 3

Class 2 Malocclusion: the mandibles are too short compared to the maxilla as in Figure 4. Note the wide gap between the upper and lower incisors and how the lower canines are now trapped to the palatal side of the upper canines. This is a serious skeletal deformity and would be considered a skeletal malocclusion.

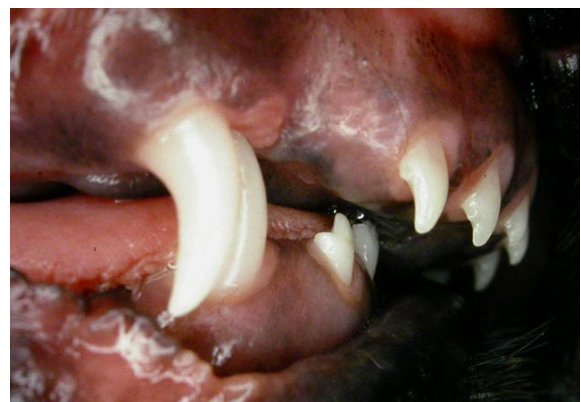

Figure 4

Craniofacial development is under genetic control and virtually all malocclusions are genetic and heritable. One possible exception would be a “wry-bite” or facial asymmetry secondary to a known trauma during development. In the absence of a known trauma that could reasonably be expected to have caused the deformity, all malocclusions should be considered genetic and heritable. Affected individuals should not be bred and neither should their parents. It might even be best to avoid breeding their litter mates.

Class 3 Malocclusion: the maxilla is too short relative to the mandibles. Sadly, this serious craniofacial abnormality is considered breed standard for a great many breeds of dog and several breeds of cats (the brachycephalics) despite this anatomy being associated with a great many liabilities that negatively impact health and quality of life. For more of my soap-box ranting on this have a look at these papers: www.toothvet.ca/PDFfiles/Stop_Brachy.pdf www.toothvet.ca/PDFfiles/Stop_Brachy_2.pdf

I could not find a photo of a class 3 malocclusion in a young puppy in my records but picture a boxer pup and you will know what I mean. The upper incisors are behind the lower incisors and often in traumatic contact with the floor of the mouth.

Class 4 Malocclusion: refers to asymmetry of the maxilla and/or mandibles when comparing the right side to the left side. The lay-term for class 4 malocclusions is “wry bite”.

More detailed descriptions of the classifications of malocclusions can be found on the nomenclature page of the American Veterinary Dental College’s website ([Nomenclature/Nomen-Occlusion](#)).

Dental Interlock

Another term I would like to introduce at this point is “dental interlock”. This refers to the interdigitation of the structures of the maxilla with those of the mandibles.

In normal occlusion, there is a normal and desirable dental interlock. If the maxilla is going through a growth spurt, the upper canine will

push on the back of the lower canine and drag the mandibles along with it. If the mandibles are going through a spurt, the lower canine and incisors will push on the palatal aspect of the upper incisors and push the maxilla along for the ride. In this manner, whichever is growing actively (maxilla or mandibles), the other is carried along by the interlock and so the desirable jaw length relationship is maintained.

With a class 2 malocclusion in which the lower canines are penetrating the palatal mucosa, this effectively staples the mandibles to the maxilla in that relationship (an abnormal dental interlock). Even the lower incisors can be a problem as they can get hung up behind the palatal rugae and incisive papilla. This abnormal dental interlock can act as a mechanical impediment to the desirable growth of the mandibles. This could mechanically prevent the mandibles from catching up. Or if the mandibles are determined to grow longer but the front cannot move forward because of the interlock and the back cannot move backward because it is held up at the TMJ, then the only option is for the mandible to bow (bend ventrally) causing more problems. The bend usually occurs in the area between the lower adult 4th premolar and 1st molar.

In a class 3 malocclusion (maxilla too short), the upper incisors will be behind the lower incisors, creating a different abnormal dental interlock. In this case the interlock would mechanically prevent the maxilla from catching up, even if the animal had the genetic potential to make that happen.

The growth of the maxilla and the mandibles are under the control of different genes. The maxilla tends to grow faster initially but the mandibles soon catch up. Maintenance of a proper jaw-length relationship depends on a proper dental interlock.

Adults erupt where?

One last bit of essential back-ground information is regarding where the adult teeth are going to erupt relative to their primary precursors. This is

important to know so you can more accurately predict what is going to happen in the weeks/months after you see a puppy or kitten for the first time. I make the following three statements with great confidence in that I have never seen an exception to them.

The adult incisors will always erupt on the lingual or palatal side of (behind) the primary teeth.

The lower adult canine teeth will always erupt on the tongue (lingual) side of the primary canines.

The upper adult canine teeth will always erupt in front of (mesial to) the primary canines.

In Figure 5, we can see the adult incisor erupting behind the primary teeth and the adult canines just starting break through the gum in front of the primary teeth. In Figure 6, we see the lower adult canines erupting on the tongue-side of the primary teeth. [NB, it is not normal or desirable for there to be primary teeth and adult teeth in the mouth simultaneously. These images are just to show where the adults will erupt relative to the primaries. All of these persistent primary teeth should be removed ASAP and that is why there were on my table.]

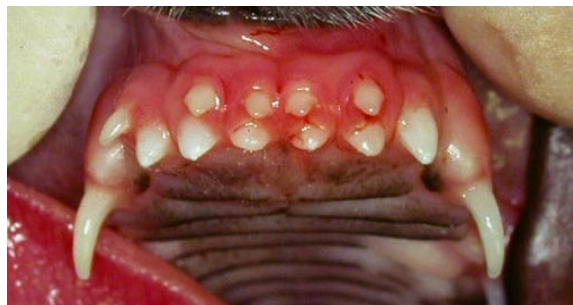

Figure 5

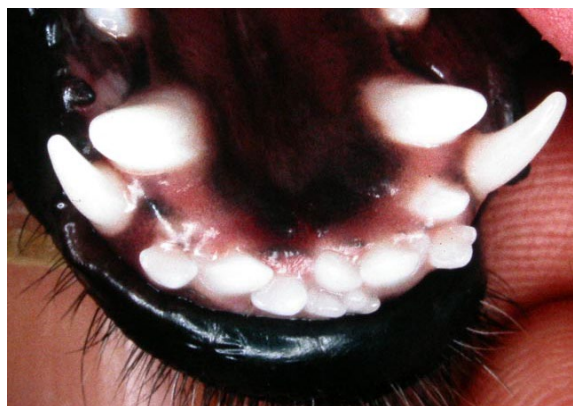

Figure 6

Why do malocclusions require treatment?

Any tooth-to-soft tissue contact has to be painful. Owners may not perceive that their pet is in distress. I discuss pets not demonstrating oral pain as Myth #1 in this paper - <http://www.toothvet.ca/PDFfiles/mythology.pdf>.

As well as what I say there I would add two more thoughts. If an animal has oral pain that is one problem. If they stop eating as a result, they now have two problems (pain and hunger/starvation). So, of course they are eating – the alternative to eating is not eating and starvation. Also, the animal usually arrives at their new home with the malocclusion in place and so the owners have never known their pet without the malocclusion. They have no normal to compare to. But we often hear that “picky puppies” become voracious eaters once the traumatic contacts have been alleviated.

So the immediate reason for treating malocclusions involving the primary teeth is to alleviate the pain associated with the traumatic tooth-to-soft tissue contacts.

The second reason for intervention with primary tooth malocclusions is to alleviate any abnormal interlocks to allow unimpeded craniofacial development so the animal can express its true genetic potential. We are trying to give the animal every opportunity to “go normal” as it grows.

What (specifically) do we do about malocclusions?

Class 1 Malocclusion.

The vast majority of class 1 malocclusions we see in puppies are lingually displaced lower primary canine teeth (linguoversion, base-narrow canine teeth). This is a problem for a few reasons.

The immediate issue is the painful trauma of having that needle-sharp lower canine perforate the palatal mucosa. Remember the inflammation in Figure 3. I have seen oronasal fistulation in dogs as young as 8 weeks of age from this.

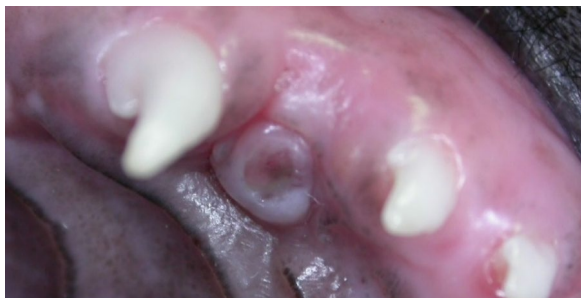

Figure 7a

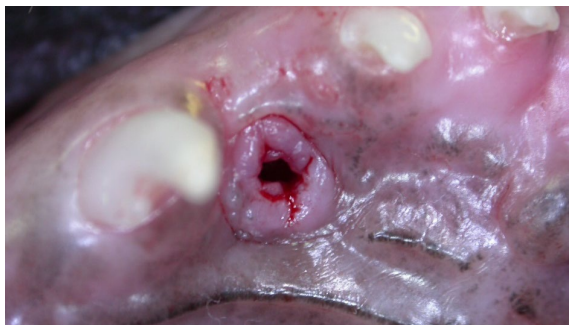

Figure 7b

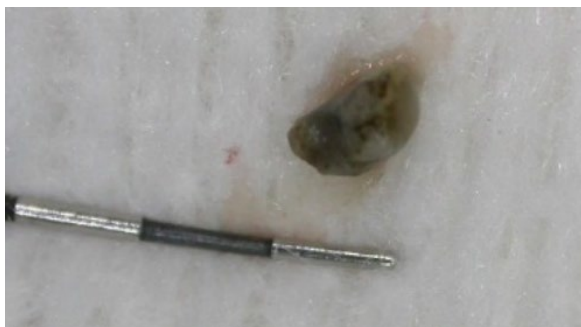


Figure 7c

Figure 7a shows the entry wound where the lower canine is perforating the maxillary soft tissue but does not really tell you how deep or serious the lesion is. Figure 7b shows the defect after debridement and 7c is the chunk of gravel I removed from the defect. In other dogs, I have pulled gravel, bird seed, wood chips and all manner of foreign material out of these defects. When the puppy is chewing on things (anything), the canine tooth pushes junk up into

According to the Veterinarian's Oath, we are sworn to use our scientific knowledge and skills for...the prevention and relief of animal suffering. Therefore, ignoring malocclusions is counter to the oath you swore when you became a veterinarian.

palatal defect and it simply will not fall out. So, more and more stuff accumulates and of course all this leads to inflammation and inflammation is painful.

The less immediate problem is that the lower adult canine tooth will erupt on the tongue side of the primary tooth – count on that as an absolute certainty (Figure 6). If the primary tooth is lingually displaced, I believe that will force the adult tooth to also erupt lingually displaced.

Treatment for lingually displaced lower primary canine teeth is immediate and careful extraction of the primary tooth and debridement of the palatal defect. This instantly alleviates the painful traumatic contact with the palate. It also creates a void in the bone where the primary root was and this is a path of least resistance through which the adult tooth can now erupt, putting it at a more desirable angle as it emerges through the gingiva. Then, as soon as the lower adult canine teeth start to emerge through the gingiva, the owners should work on [Ball Therapy](#).

In many cases, timely extraction of the primary canine and use of Ball Therapy as the adults are erupting will do the trick and no further intervention will be needed.

Class 2 Malocclusion

Some class 2 malocclusions are minor enough (just off by a millimeter or two) that the lower canines are not causing any trauma and no treatment is needed. Sometimes, a slightly less mild case does need intervention but can be managed like the class 1 situation I discussed above (remove the primary canines early and Ball Therapy as the adults are erupting).

With more significant class 2 malocclusions (Figure 4), we have the same concern of the lower canine causing trauma to the palate. There is also the concern about the abnormal dental interlock with the canines stuck in the palatal mucosa and the lower incisors getting caught up behind the palatal rugae and incisive papilla.

We can deal with both concerns via immediate and careful extraction of the lower primary canines and incisors. This alleviates the traumatic contacts (and associated pain) and it allows the mandibles to grow without mechanical impediment.

Orthodontics is a game of millimeters and while photographs can be of some value in assessing the situation, nothing beats seeing the patient live and in 3D.

It is very important for all, especially the owners, to understand that removal of the primary teeth does not cause the mandibles to grow faster. It simply allows for unimpeded mandibular growth. The genetic programming has to be in place for this to happen and it rarely is. Some practitioners refer to this as “pull and pray”. We remove the primary teeth to alleviate the trauma and hope that the mandibles will catch up, realizing that they probably will not. Therefore, the owners should expect that more work will be required when the adult teeth erupt.

It is also important to know that when the lower canines are palatal to the upper canines because the mandibles are too short, Ball Therapy will be of no use. Ball Therapy only works when the

I have heard of breeders and even veterinarians clipping the deciduous canine teeth with nail trimmers or wire cutters rather than extracting them. I feel this should be grounds for a criminal charge of cruelty to animals. It would certainly be professional misconduct to needlessly inflict pain and suffering on an animal. Imagine if I were to cut your teeth in half and leave the pulp exposed.

Our understanding of pain perception in animals has come a long way and it is no longer reasonable to justify barbaric treatments on the assumption that puppies do not feel pain. If a puppy has a traumatic malocclusion with the lower canine teeth traumatizing the palate, the treatment is extraction of the deciduous canines, under general anesthesia. If that is not an option, then do nothing as it would be far less painful and harmful than cutting the teeth and leaving the pulps open to infection.

lower canines just have to tip out towards the lip and there is nothing blocking their path to a desirable location.

Class 3 Malocclusion

If the patient is a member of a brachycephalic breed (or is a mix with a brachycephalic parent), there may be no point in doing anything with the primary teeth. Nothing we can do will undo the generations of selective breeding that has caused this serious craniofacial deformity. I typically suggest that nothing be done with the primary teeth but that the owners should start budgeting for considerable work to be done at about 6 to 7 months of age to make the best of a very bad design.

If the patient is not of brachycephalic breeding and the malocclusion is relatively mild, then removal of some primary teeth to alleviate any abnormal interlocks might be worthwhile. This would also fall under the heading of “pull and pray”.

Typically, the rule is to extract teeth for the short side and so in a class 3 malocclusion, this would mean removing the upper incisors. But it is important to look carefully at the biomechanics of the mouth live and in 3D. You want to remove teeth that are causing trauma and abnormal interlocks and leave teeth that would provide beneficial interlock in place.

Timing

So far, we have been talking about extraction of primary teeth to alleviate the trauma of tooth-to-soft tissue contacts +/- remove abnormal dental interlocks. I have not yet been specific about when this should be done so it is time to address that now.

If you detect a malocclusion when you see a puppy for its first evaluation at 8 weeks of age, that is the time to do the extractions. The sooner you remove the offending teeth, the less time the animal has to live with painful contacts and the more time there is for things to improve before the adult teeth erupt.

There would still be benefit to the patient in doing these extractions at 12 weeks of age, even at 16 weeks of age, but the longer you wait, the longer the pup has been in pain and the less time

before the adult teeth erupt. The value of intervening diminishes with every week that goes by and drops off dramatically after 16 weeks of age. By 20 weeks, we might as well not bother. Just wait for the primary teeth to fall out on their own and deal with the problems the adult teeth create at 6 to 7 months of age.

Caution about primary extractions

It is well beyond the scope of this paper to teach extraction technique, especially primary extractions, but I will make a few points.

- Intra-oral dental radiographs are an absolute must. You need pre-op images to visualize the primary roots and the developing adult tooth buds. You also need post-op images to document that you got the primary roots out.
- The primary tooth roots are very long, thin and thin-walled. Figure 8 is a radiograph of the rostral mandible and it demonstrates this. Therefore, you need a delicate touch and patience to get them out without breaking the roots. Figure 9 is of extracted lower primary canines and incisors, again showing how long and fine these roots are
- The developing adult tooth buds are right beside the primary roots and are in harm's way during primary extraction of the primary teeth. You need to be very careful to avoid elevating in the area of the developing adult teeth. Damage to the developing adult teeth is a very real risk of primary tooth extraction and if you are questioning your ability to get the primary teeth out without damaging the adult teeth, then you should refer the case.
- You need small, sharp instruments for working on the small, delicate primary teeth of puppies and kittens. If you do not have the appropriately-sized instruments for this, then again, you should refer.

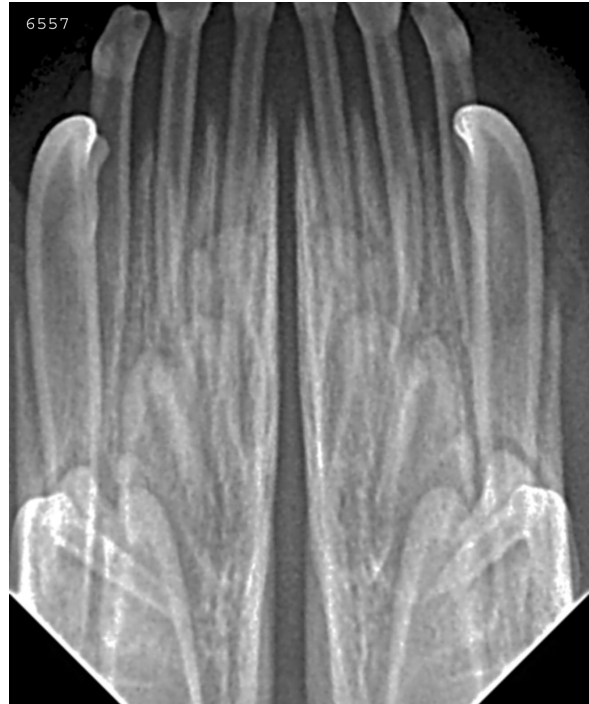

Figure 8



Figure 9

During the Mixed Dentition Phase

Around 4.5 to 5 months of age, the primary teeth start to exfoliate as the adult teeth start to erupt. This typically begins with the 1st incisors and progresses to the 2nd and 3rd incisors, canines and then on to the premolars. All of the primary teeth should be gone and the adult teeth should have all made an appearance (may not yet be fully erupted) by to 6 to 6.5 months of age. The period of primary exfoliation and adult eruption, when there are teeth of both types in the mouth simultaneously is known as the mixed dentition phase. This phase is often not observed by the veterinarian who sees the pet at 4 months for final vaccines and not again until 6 months for spay/neuter. Therefore, I recommend that clinics plan on an oral development visit at 5 months of age just to keep an eye on the situation. A lot is



Check the whole litter.

happening between 4 and 6 months of age and windows of opportunity to intervene when there are problems can close fast.

If there has been a malocclusion in place that went undetected or untreated until the mixed dentition phase, it is likely too late to do anything of value with the primary teeth and too early to do anything with the adult teeth. We just have to wait a bit longer and deal with the adult teeth once they have erupted.

Persistent Primary Teeth

An exception to that would be when the primary teeth fail to exfoliate on time. We never want there to be two teeth occupying the space meant for one. In other words, if the adult tooth is showing itself and its primary counterpart has not fallen out, get it out ASAP.

In Figure 10, the upper left primary canine tooth is occupying the space meant for the erupting adult tooth. This is forcing the adult tooth to erupt too far forward in the mouth so there is too little space between it and the 3rd incisor (the space that is supposed to accommodate the crown of the lower adult canine). This will trap the lower adult canine tooth on the palatal side of the upper canine and force the lower canine into traumatic contact with the maxillary tissues.

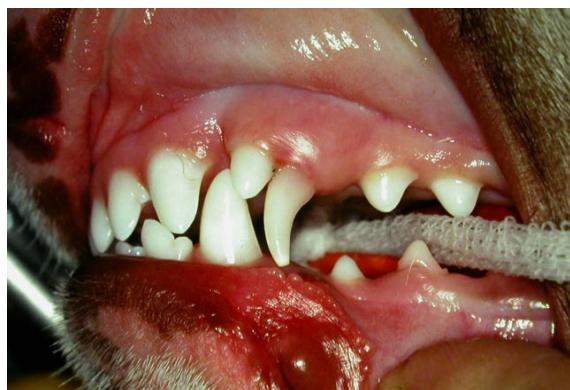

Figure 10

With immediate extraction of the primary canine tooth, the upper adult tooth can drop back into its proper position, opening the space and allowing the lower canine to tip out properly. If you wait too long, the adult canines will be too far along their eruption path for the extraction of the primary tooth to make any difference and much more complicated (and expensive) orthodontic treatment will be required.

Similarly, if the lower primary canine tooth persists as the adult tooth is erupting (even if the primary had been properly positioned all along) the adult tooth, which will always be on the tongue side of the primary (Figure 6), will be forced to erupt base narrow, driving it up into the palate. So, get the primary tooth out right away and if the jaw length relationship is normal or close to normal, adding [Ball Therapy](#) would also be a very good idea.

Malocclusions of the Adult Teeth

Back to background. The dental formula of the adult teeth in dogs is 2 x I3/3, C 1/1, P 4/4, M 2/3 and for cats 2 x I3/3, C1/1, P3/2, M1/1. In dogs, particularly, there are a lot more adult teeth (42) than primary teeth (30) and they are considerably larger, so the opportunities for malocclusions are greater. With more teeth and larger teeth, we can still see abnormal tooth-to-soft tissue contacts but now we are more likely to also see abnormal tooth-to-tooth contacts, crowding, rotation and under-eruption problems.

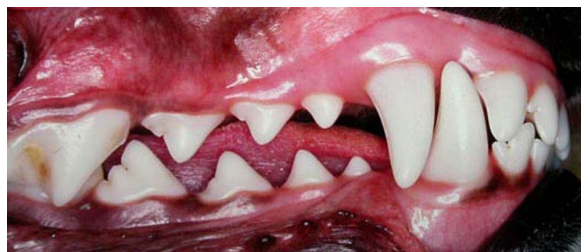
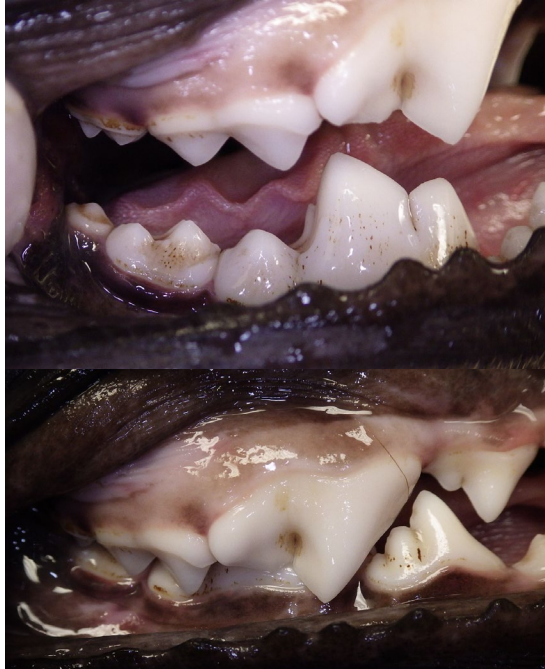
Figure 11

Figure 11 shows the right side of a normal mouth. The lower incisors are just behind the uppers, the lower canine fits right into the centre of the space between the upper 3rd incisor and canine, the premolars are in a pinking-shear alignment (tip of one tooth points to the space between adjacent teeth of the opposing jaw) and the upper 4th premolar is on the labial side of the lower 1st molar, brushing past it like one blade of a pair of scissors. In this photo, there is not tooth-to-tooth contact, no tooth-to-soft tissue contact, no crowding, no rotations, no under-eruption. The only place there should be any tooth-to-tooth contact in a dog is at the molars. The upper 1st molar contacts the distal third of the lower 1st molar and the mesial half of the lower 2nd. The upper 2nd molar contacts the distal half of the lower 2nd and all of the lower 3rd molar as shown in Figures 12a and 12b.



Figures 12a and 12b

No malocclusion should ever be considered normal, regardless of the breed. In some breeds, where malocclusions are selected for, they are “Abnormal in accordance with current breed standards.” As advocates for animal health and welfare, we should all be campaigning to get these standards changed. Every animal deserves a comfortable and functional mouth. There is no logical, moral or medical justification for purposely producing animals with deformities that have a negative impact on their quality of life.

Class 1 Malocclusions

The most common class 1 malocclusion we see is base narrow mandibular canine teeth. If the jaw length relationship is good and there is space between the upper 3rd incisor and canine, it is often possible to get the lower canine to tip out labially using [Ball Therapy](#). This is a very simple, inexpensive option that anyone can offer. It is best to start ball therapy as soon as the lower adult canine teeth start to show themselves erupting through the gingiva.

If Ball Therapy does not work, there are some fixed orthodontic appliances that can be used to tip the lower canines labially. Placement of these devices would be considered NFCO = [Not For the Casual Operator](#) and would require referral to someone with training in orthodontics and use of the materials involved.

One option is crown extensions as shown in Figure 13. These are made of composite resin, bonded to the tips of the erupting adult canine teeth, under general anesthesia and then removed (under anesthesia again) after the teeth have moved sufficiently (typically in 4 to 6 weeks).

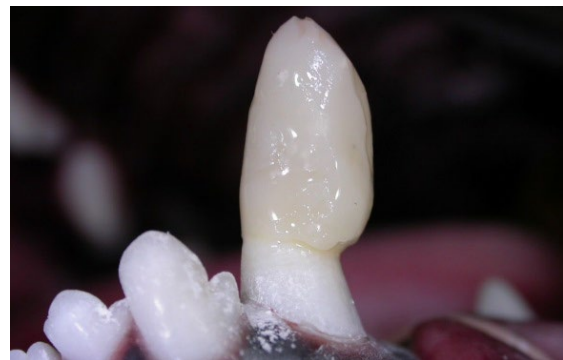

Figure 13

Another option is inclined planes, again made of dental composite, but this time, bonded to the upper canines and 3rd incisors as in Figure 14.

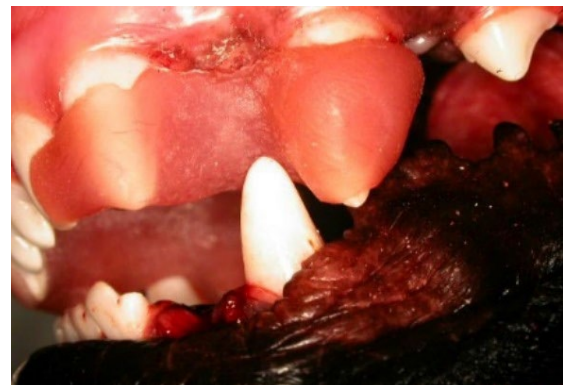

Figure 14

Incline planes are also placed and removed under general anesthesia at visits typically 4 to 6 weeks apart.

The use of either of these fixed appliances needs to wait until the teeth have erupted sufficiently that there is enough of the crowns out in the open to attach the materials to. Composite extensions can go on a bit earlier (around 6 months or so) but incline planes need to wait

until the upper canine and 3rd incisors have erupted fully so that the appliance does not interfere with their eruption (so seven months or so depending on the patient).

Another point with fixed orthodontic appliances is patient selection. If we place appliances in the mouth, we have to know that the owners will be able to manage the patient so that they do not damage/dislodge the appliances before they are due to be removed. Not every dog and not every owner are good candidates for the use of fixed orthodontic appliances.

The fourth option for base narrow canines in a Class 1 malocclusion is [Crown Reduction](#), which typically needs to wait until seven months of age at least. Figure 15a shows lower canines after crown reduction that took them out of contact with the maxilla and Figure 15b is an immediate post-operative radiograph of the lower left canine crown showing the various materials placed inside the tooth to protect the remaining pulp tissue and seal the tooth against bacterial ingress.

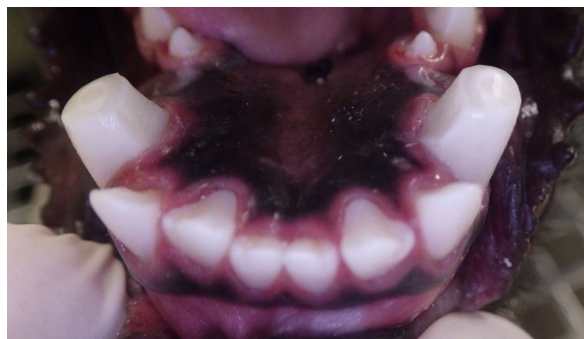

Figure 15a

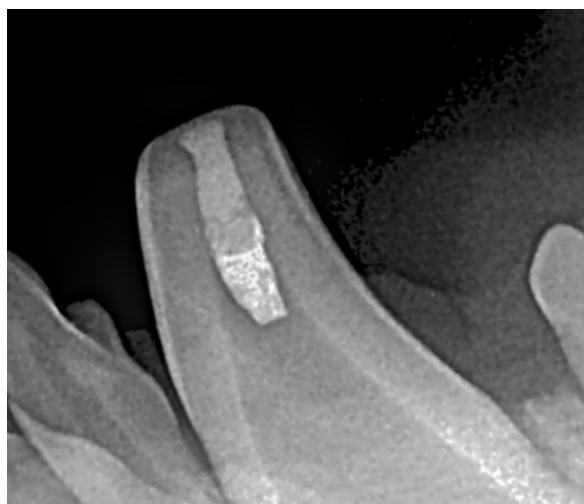


Figure 15b

Another relatively common Class 1 malocclusion is rostrally displaced maxillary canine teeth (Figure 16). This is most common in Shetland sheepdogs but can be seen in others. Here is my very old paper on that – [Lance Canines](#). While some of my colleagues might try to reposition these teeth with active force orthodontic appliances, my approach is to simply extract the misaligned (and therefore useless) canine tooth. This is a one-stop, permanent solution that is far simpler to perform.

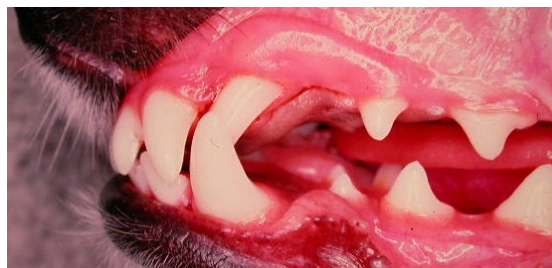


Figure 16

Class 2 Malocclusions.

When the mandibles are significantly too short compared to the maxilla, this often places the lower adult canine teeth palatal to the uppers, forcing the lowers to dig into the palate as in Figure 17. In such cases, the only alternative to extraction of the lower adult canine teeth is [crown reduction](#).

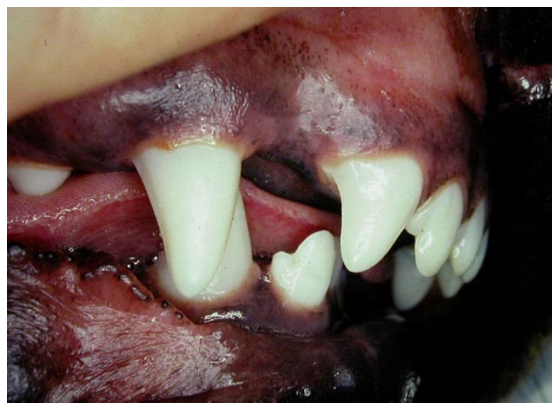

Figure 17

Sometimes the mandibles are so short, the lower canines are actually behind (distal to) the maxillary canines and can be out at an acceptable angle so that they are causing no significant trouble and there may be no treatment needed (Figure 18).

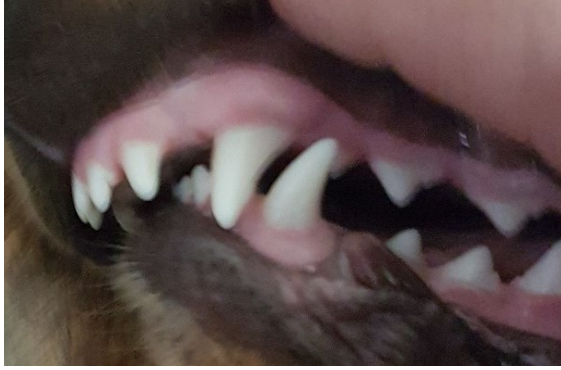


Figure 18

There is sometimes some minor palatal trauma from the lower incisors in a class 2 malocclusion and I usually manage that at the same time as the canine crown reductions by doing a bit of odontoplasty and dentin bonding (NFCO) to shorten and blunt the lower canines a touch.

Class 3 Malocclusions.

I have already written a lengthy paper on animals with this very common malocclusion and so rather than re-writing it her, I am just going to give you the link - [Brachy Issues](#).

To summarize, brachycephalic dogs have a host of oral issues related to their distorted craniofacial anatomy:

- Upper incisors traumatize the floor of the mouth and the lingual aspect of the lower canines.
- The upper premolars are crowded and rotated predisposing to periodontal disease
- The canine teeth and several others may be under-erupted predisposing to [pericoronitis](#).
- There may be various other traumatic contacts.
- There may be “[furry palate](#)”
- They may have [caudal buccal traumatic granulomas](#)

Treatment of most of the issues associated with brachycephalism and class 3 malocclusions is typically centred on extraction of teeth that are causing problems or are at great risk of getting into trouble. These animals need a lot of [pro-active care](#) to give them a reasonable hope of acceptable oral health.

Conclusion

As I said at the outset, this has been just a very brief introduction to malocclusions and how they may be managed. Most of the treatments are NFCO and require referral to someone with advanced training in veterinary dentistry. Coordinating with that person is another important subject. Different people may have different ways of going about this, but if you see a case you think you would like my help with, here is how I would like you to proceed.

We are often booked up for two to three months in advance but malocclusions in young, growing animals have narrow windows of opportunity. When managing malocclusions, we are usually squeezing the cases into an already full schedule. To help us to do that, when you first see the animal:

- Do not take a wait-and-see approach but get the ball rolling as soon as you notice trouble.
- Grab blood for preanesthetic testing (CBC with platelet count and biochemical profile) and have the results, along with your interpretation of them forwarded to me by email (toothvet@toothvet.ca) or fax (519 763 6210)
- Get some good, in-focus photographs such as in Figure 19 a, b and c. In the first two, the mouth is closed but the lips retracted so I can see where the teeth of the maxilla are going in relation to the mandibles and vice-versa and I can see the jaw-length relationship. The images are up-close, well-lit and in focus. I want to see lateral images from both sides and one from the front. The third image is an open-mouth view of the maxilla showing the traumatic defects in the palatal mucosa. Email the images to toothvet@toothvet.ca. Include signalment in the body of the email (age, breed, weight) and some history. Send the images as jpeg file attachments, NOT embedded in the body of the message.
- When sending me anything by email, use the pet's first and last name as the subject line in the email (Scruffy Jones).

- Complete the [referral request form](#) (fully and legibly) and fax it to 519 763 2468.
- After sending images and the referral form, you can call to discuss the situation. Please note that if you call before you send the images, I really will not be able to tell you much other than asking that you get me the images so I can be sure we are on the same page and that I am giving you appropriate recommendations.
- After sending the images and referral form, have the owners contact us by phone (numbers below) to schedule their appointment. You cannot book the appointment for them and we will not make the first contact. They have to call us, and it should be between 9:00 and 3:00, Monday to Friday.

Keeping these guidelines in mind will help me to help you, your patient and your client with a maximum of efficiency.

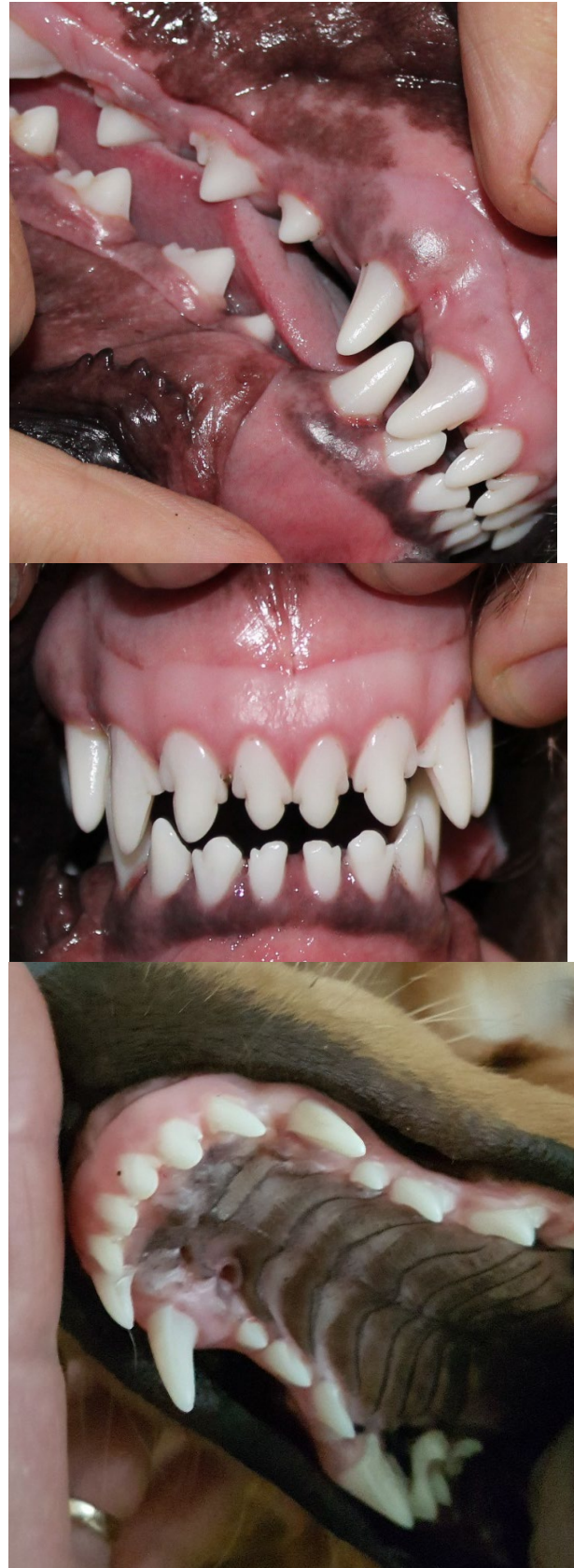


Figure 19a, b, c