

Lance Canines: An Illustrated Exploration

I would like to discuss a recent case of a young sheltie with a couple of dental problems.

The first problem was a common one in shelties and is variably called *lance canines*, *rostrally displaced maxillary canines* or *mesially displaced maxillary canines*. Whatever name you choose, the problem is that the permanent maxillary canine teeth erupt pointing in the wrong direction.

To understand a problem, you must first understand normal so I will review the normal relationship of the *canine triad*. The canine triad is composed of the maxillary lateral incisor and the canine teeth on one side and is depicted in Figure 1. In this picture, you can see that the crowns of the canine teeth are basically vertical. There is a large space between the maxillary lateral incisor and the maxillary canine and this space is known as a *diastema*. When the mouth is closed, the mandibular canine crown resides in the centre of the diastema so that it does not contact either of the other teeth in the triad.

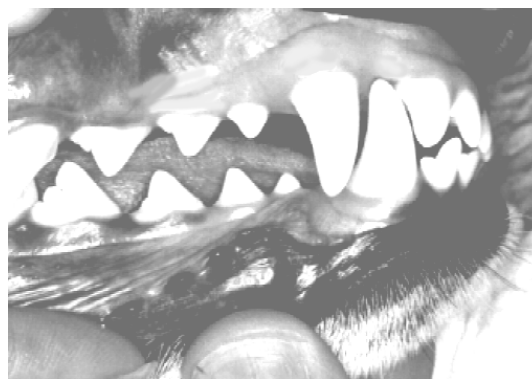

Figure 1: The normal canine triad.

In affected shelties, one or both of the maxillary canines is malpositioned so that it is lying more horizontally. As such, the crown crosses the diastema and blocks the mandibular canine out as in Figure 2. Now on closure, the mandibular canine contacts the maxillary canine and is often forced to tip labially. Owners notice this because the mandibular canine then starts to catch on the upper lip.

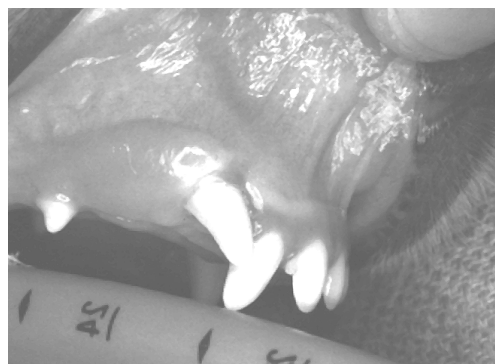

Figure 2: An affected dog with the right maxillary canine directed mesially and blocking the diastema.

There is variability in the degree to which the maxillary canine is malpositioned. Figure 2 shows a relatively moderate situation. Figure 3 is a radiograph of a dog with a much more severe situation in which the canine tooth is almost horizontal. Only the very tip of the crown erupted through the gingiva and this tip was contacting the lateral incisor on the distal aspect.

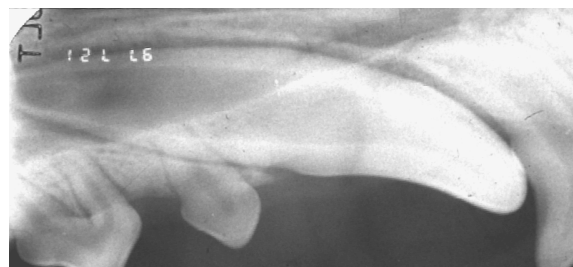


Figure 3: Radiograph of the right maxillary canine tooth in a sheltie with a severe malposition.

So what? Why is any of this a problem? Well, for one thing, I already mentioned that it is common in shelties and rare in other breeds. That would indicate that we are dealing with a heritable problem. Therefore, affected individuals would be unsuitable for the show ring and for breeding, regardless of what corrective procedures are undertaken. Orthodontic repositioning of these teeth does not affect the genetic make-up of the dog!

Another problem with this condition has already been mentioned. The lack of a diastemal space for the mandibular canine crown causes it to tip labially and traumatize the upper lip. There will

also be attrition as the crowns of the maxillary and mandibular canines rub on each other. Abnormal tooth-to-tooth contacts such as this should always be considered a problem worthy of attention.

Probably the greatest concern about rostrally displaced canine teeth is the great increase in risk for periodontal infection that they present. To understand why that is, we have to review some periodontal anatomy and physiology.

The periodontium is the group of tissues that support the tooth. This includes the *gingiva*, the *alveolar bone*, the *periodontal ligament* and the *cementum*.

Cementum is a specialized tissue that covers the roots of the tooth and acts like the periosteum for the root. It is the only dental tissue to which the periodontal ligament fibers will attach. It is also the only dental tissue to which the gingiva will attach.

In the normal situation (as depicted in figure 4), the enamel of the crown is largely out in the open. There is small strip of enamel is below the gingiva and since the gingiva does not attach to enamel, this gingiva is called the *free gingiva*. The space between the enamel and the free gingiva is known as the *gingival sulcus*, and in health it is really only a potential space as the gingiva wraps tightly around the tooth. The sulcus is typically between 1 and 3 millimeters deep in dogs.

Where the enamel stops, the cementum begins, at the *cementoenamel junction*. In health, this is where the gingival attachment begins, starting with the *epithelial attachment* below which is the much firmer *connective tissue attachment*. Once within the confines of the boney socket (*alveolus*) the periodontal ligament fibers run from the alveolar bone to the cementum.

Now consider a case such as in the radiograph in figure 3. In that dog, the majority of the enamel covered crown is buried below the gingiva and in the alveolus. This creates a very deep “gingival sulcus”, or more accurately, a deep periodontal defect. This space will soon become colonized with oral plaque bacteria. These bacteria, protected within this deep pocket, will find life quite easy and *periodontitis* will soon set in. Periodontitis is not only a local concern, but also a source of bacteremia that may have effects on organs far removed from the mouth. It is not a healthy situation and requires our attention.

The treatment goal for deep periodontal pockets is to decontaminate the hard and soft tissues that line the pocket so that the periodontal ligament and gingiva can reattach to the root surface and reduce the pocket depth. In cases of under-erupted teeth, no matter how clean you get that buried enamel surface, periodontal ligament fibers and gingiva will never attach to it. The deep pocket remains and infection is soon re-established.

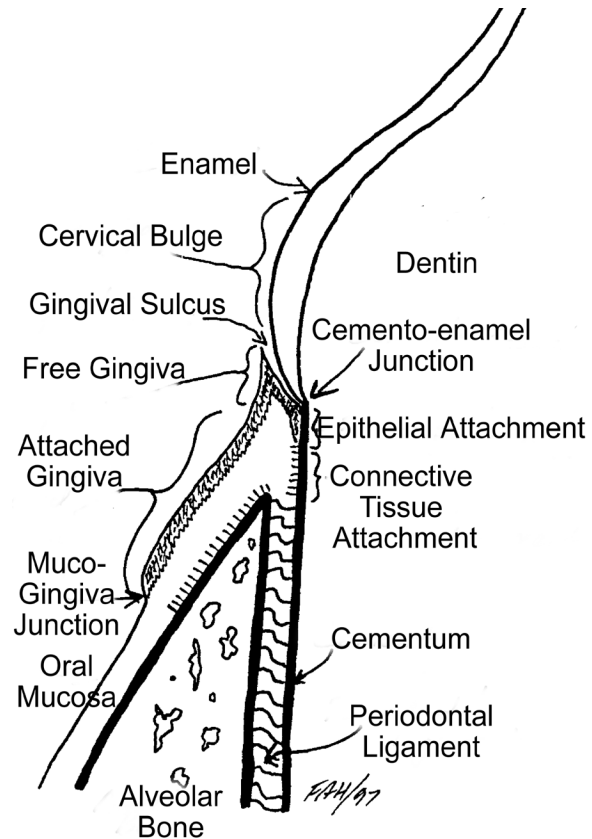


Figure 4: The relationship of the periodontal tissues to the tooth.

Now that we understand the problems associated with lance canines, what are the treatment options? To a large degree, that depends on the severity of the displacement, the owner's desires and the attitude of the dentist offering the options. For all options, the main treatment goal is to give the dog a comfortable, healthy mouth. A "normal bite" may or may not be in the cards.

One option is to use orthodontic buttons and brackets bonded to the canine and some anchor teeth and elastic chain to slowly tip the canine into the desired location. Though possible, this treatment is quite involved and is considered by some to be excessive. Bear in mind that if we are trying to tip the maxillary canine crown down and back, each time the dog closes its mouth the mandibular canine is there to push the maxillary up and forward again.

Another option, and the one that I usually find most rational, is to extract the misplaced maxillary canine. This opens the diastema and allows the mandibular canine to drift back where it belongs. It also removes the deep periodontal pocket and so makes the mouth much healthier.

I mentioned that the case I saw recently had a couple of problems. He did have a lance canine on the right. His other problems were found in the right rostral mandible and are depicted in the radiograph in figure 5.

This dog's right mandibular canine was also misplaced. This one radiographic view does not actually do the problem justice. The canine tooth was almost totally unerupted (embedded), lying within the mandible under the tongue. Only about 2 millimeters of the crown were visible in the oral cavity, lying just lingual to the incisors. The intermediate and lateral incisors were rotated approximately 90 degrees. With most of the crown of the canine buried, we had the same periodontal concerns as for the maxillary tooth. Treatment involved removal of this canine tooth and the right mandibular incisors, as they had no periodontal bone support.

My theory on the mandibular canine is as follows. When the tooth was developing, its tip was pointing rostrally instead of dorsally. As the tooth grew, the crown "erupted" rostrally within the mandibular bone until it struck the roots of the incisors. At this point, the crown could not go forward, so as the tooth got longer, the apex of the root had to move backward. Notice that the apex of the left canine is below the second premolar (where it belongs) but the apex of the right canine is below the third premolar.

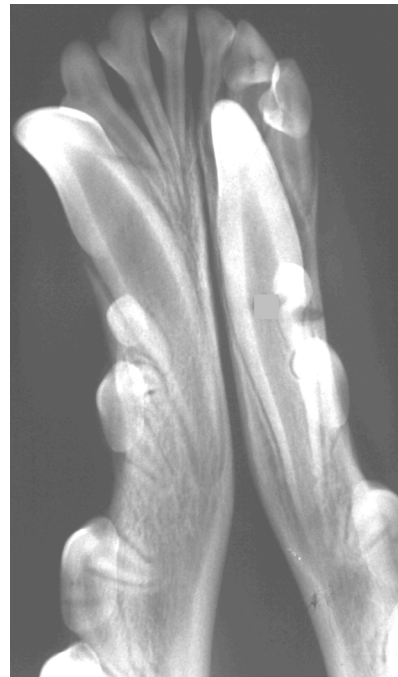

Figure 5: Radiograph of the rostral mandible of a young sheltie with a misplaced right canine tooth.

The problem with the maxillary canine in this dog was that the tip of the crown was pointing rostrally, not ventrally. This is an old problem in shelties. The problem in the lower jaw seemed almost identical. I wonder if we are seeing the emergence of a new, heritable condition affecting the mouths of shelties. Please be on the lookout for this.

If you see shelties with malpositioned canine teeth, the first step is to neuter the dog. Then get the mouth looked after.