

# Juvenile Veterinary Dentistry

It is often assumed that dental problems are reserved for the aged. Certainly, the incidence and severity of periodontal disease and other oral problems increases with age, but young animals may also suffer from a number of dental and oral maladies. Often, early recognition and treatment of these problems can prevent more serious complications in later life. Also, many of these problems are painful and so require treatment to alleviate suffering. This article will cover some of the more common dental concerns in animals during their first year of life. It is my intent to teach you to recognize these problems and their significance and to understand that treatment is both indicated and available.

When a puppy or kitten is presented for a check-up at eight weeks of age, it should undergo a thorough oral examination. By this age, the deciduous teeth should be well erupted and in place. There should be no clefts or defects in the hard or soft palates or in the lips. The upper incisors of the puppy should just slightly overlap the lower incisors and the lower canine tooth should be placed between the upper lateral incisor and the upper canine tooth. In kittens, the lower canine should be positioned as in the puppy, but the incisors may meet tip-to-tip in a level bite.

As the growth of the mandible and maxilla are under separate genetic control, the growth of one only influences the growth of the other in so far as they are “locked” together by the interdigitation of the teeth. If the teeth are properly positioned, as the maxilla grows, its upper canine can push on the back of the lower canine and “drag” the mandible along. As the mandible grows forward, its incisors hit the back of the maxillary incisors and “push” the maxilla ahead. In this way, the proper mandible-maxilla relationship should be maintained throughout the growth period and into adulthood.

If the young puppy or kitten has a significant jaw length discrepancy so that there is an abnormal dental interlock (lower canines digging holes in the hard palate or upper incisors trapped behind lower incisors) then the potential for the abnormally short jaw to catch up is mechanically impeded.

In the example of an eight-week-old puppy with a short mandible, the lower canines will often dig into the hard palate and the incisors will be trapped behind the incisive papilla of the hard palate. If the lower jaw attempts to go through a growth spurt to catch up to the maxilla, the interlock holds it back. The result can be that the mandible remains abnormally short or it may bend in the middle and bow ventrally.

A puppy or kitten with an obvious malocclusion is a candidate for *interceptive orthodontics*. Interceptive orthodontics involves selective extraction of any deciduous teeth that would impede the development of a proper bite. The general rule is to extract the teeth from the short jaw. These procedures do not alter the animal’s genetic make-up nor do they **make** anything happen. Rather, they **allow** the animal to express its full genetic potential by removing any mechanical impediment to growth. Owners and breeders should be cautioned that, even if the animal turns out normal, it required intervention and so should be bred very carefully if at all. A safer recommendation would be to neuter these animals at an appropriate age.

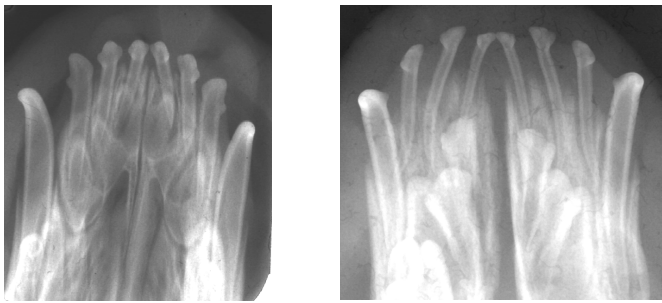
A second benefit of interceptive orthodontics is that it immediately relieves the oral trauma and pain associated with abnormal tooth-to-tooth or tooth-to-soft tissue contacts. A puppy that goes through its socialization period with a sore mouth is more likely to become head shy and difficult to handle.

To maximize the benefit of interceptive orthodontics, it should be performed as soon as possible. The hope is that the jaw length relationship will normalize before the permanent teeth erupt and recreate dental interlock. The more time between deciduous tooth extraction and permanent tooth

eruption, the better the chances of success. Therefore, I like to see these dogs at about eight weeks of age.

It is beyond the scope of this article to outline the procedure for deciduous tooth extraction but some general comments are appropriate.

- Always take a pre-operative, intra-oral, dental radiograph to document the presence and location of developing permanent teeth.
- Extraction of deciduous teeth calls for very fine, delicate instruments such as West apical root tip picks. Using your standard elevators will likely cause significant trauma to soft tissues, bone and developing tooth buds.
- Elevate *very carefully or not at all* in the area of the developing permanent teeth to avoid damaging them. Developing permanent teeth can be seriously mangled by careless extraction of deciduous teeth. As the radiographs below indicate, the roots of the deciduous teeth are very long and the permanent tooth buds are all crowded around them.



---

Over the years, I have had a number of breeders and colleagues ask about clipping the deciduous canine teeth, with nail trimmers or wire cutters, rather than extracting them. **I feel this should be grounds for a criminal charge of cruelty to animals.** It would certainly be professional misconduct to needlessly inflict pain and suffering on an animal. Imagine if I were to cut your teeth in half and leave the pulp exposed. Did you see the Marathon Man? Our understanding of pain perception in animals has come a long way in recent years and it is no longer reasonable to justify barbaric treatments on the assumption that puppies do not feel pain. If a puppy has a traumatic malocclusion with the lower canine teeth traumatizing the palate, the treatment is extraction (or crown reduction with partial vital pulpotomy and direct pulp capping under general anesthesia) of the deciduous canines. If that is not an option, then do nothing as it would be far less painful and harmful than cutting the teeth and leaving the pulps open to infection.

---

Deciduous canine teeth are long and thin and are found in the mouths of puppies. These three factors make them very subject to wear and fracture which will expose the pulp of the tooth. The pulp is the soft tissue that is found inside a tooth and consists of blood vessels, nerves, lymphatics and connective tissue. Once exposed to oral bacteria, the pulp quickly becomes infected and dies. During this time, there is significant pain, but once the pulp is dead, the pain subsides. Next, infection oozes out through the root tip into the periodontal space around the root. The periapical inflammation will be painful. It can also cause osteomyelitis, a draining fistula and damage to the developing permanent teeth.

The treatment for all deciduous teeth with exposed pulps is immediate and careful extraction of the entire crown and root. If the fracture is chronic (more than a few days), you must consider the root contaminated and so if a piece breaks off, it should be retrieved. However, you do have to be very careful about damaging the permanent teeth. It is far better to elevate very carefully and patiently and extract the tooth intact than to rush and break it.

Some veterinary dentists suggest that, in some cases, endodontic treatment of deciduous teeth might be appropriate. All agree, however that it is **not** appropriate to do nothing and just wait for the tooth to fall out on its own. A deciduous canine tooth broken when a puppy is 12 weeks old will still be there, causing trouble up to 2 months later. That's a long time to leave a painful infection untreated.

---

By the time a pet is presented for rabies vaccine around 4 months of age, some of the permanent incisors should be erupting. The permanent canines and some of the premolars may also be erupting by this time. It is at this stage that we should all be looking for persistent deciduous teeth. This is a problem commonly associated with small breed dogs, but I have seen it in cats and large breed dogs as well.

The rule is that if the permanent tooth crown is visible above the gum-line, then the deciduous tooth should be gone. If the deciduous tooth is still in place, it should be removed as soon as possible. Leaving a persistent deciduous tooth in place until six months (spay/neuter time) is inappropriate as it forces the permanent tooth to erupt into an abnormal location. The interactions are complex, but very simply, if the deciduous tooth is in place while the permanent is erupting, you have two teeth occupying the space meant for one and this will cause problems.

---

An animal presented for spay/neuter at about six months of age represents a golden opportunity. The animal will be under general anesthesia and so you can do an unhurried, thorough oral examination. In most breeds, all permanent teeth should be partially or fully erupted by this age. During your examination, you should note any missing or extra teeth, deformed or malpositioned teeth and any other situations that might predispose to problems.

“Missing” teeth should always be documented with an intra-oral radiograph. If the radiograph shows that the tooth is missing then it can be recorded as such on the animal's permanent dental record for future reference. Though this may be of no functional significance to the animal (depending on which tooth is missing) some breed standards require a full set of teeth and so the breeder should be informed of this developmental abnormality.

If the radiograph shows a tooth that is unerupted for any reason then its extraction should be recommended. This extraction should not be done at the same time as a sterile procedure due to the increased risk of infection at the sterile site. The finding of an unerupted tooth should be recorded on the animal's chart and the extraction scheduled for sometime prior to the animal's first birthday. Failure to detect and extract an unerupted tooth will often lead to the development of a dentigerous cyst. These cysts, while benign, are destructive of bone as they expand which can lead to loss of adjacent teeth. They have also been reported to undergo malignant transformation.

Extra teeth also call for an intra-oral radiograph to determine if you are seeing two completely separate teeth or two crowns sharing a common root and pulp system. If you find that there are two completely separate teeth and the extra tooth is causing a crowding situation, it should be extracted in the near future.

Many brachycephalic and small breed dogs will have severe crowding and rotation of teeth. This can lead to food impaction and early onset of periodontal disease. The suggested treatment is selective extraction of less significant teeth to relieve the crowding and improve the periodontal prognosis for the remaining teeth. If there are three teeth crowded together, then removal of the middle one may improve the outlook for the other two. Failure to do this can lead to chronic periodontal infection and loss of all three teeth within a few years.

Most orthodontic problems lead to abnormal tooth-to-tooth or tooth-to-soft tissue contacts. The resulting trauma can cause a variety of problems including periodontal disease, root resorption, oro-nasal fistulae and endodontic (pulp) disease. The treatment varies depending on the specifics

of the condition but may involve selective extraction, crown reduction or orthodontic movement of teeth to alleviate the abnormal contacts.

---

Young animals may suffer fractures of permanent teeth as a result of inappropriate chewing habits or accidental trauma. If treated soon, these teeth can often be saved through partial pulpotomy and pulp capping. This procedure leaves living pulp in the root of the tooth so that it can continue to develop. The prognosis is good if the tooth is treated within 24 hours of fracture but the prognosis decays exponentially as time passes. Once the pulp is irreversibly inflamed the treatment options are limited and the long-term prognosis for the tooth is guarded. Therefore, crown fracture and pulp exposure in a young animal constitutes a time-critical dental emergency. If you see one, call me immediately, any time of the day or night, any day of the year and I will do what I can to see the patient while our chances of success are still good.