

WHOLE MOUTH EXTRACTION FOR EVERYONE

[There are hyperlinks in the text and some of the following images also have hyperlinks to papers that discuss the relevant issue in more detail]

This is an intentionally provocative opinion piece but only partially facetious. My hope is to stir the pot a bit and encourage small animal veterinarians to take a hard look at how they approach the oral health of their patients.

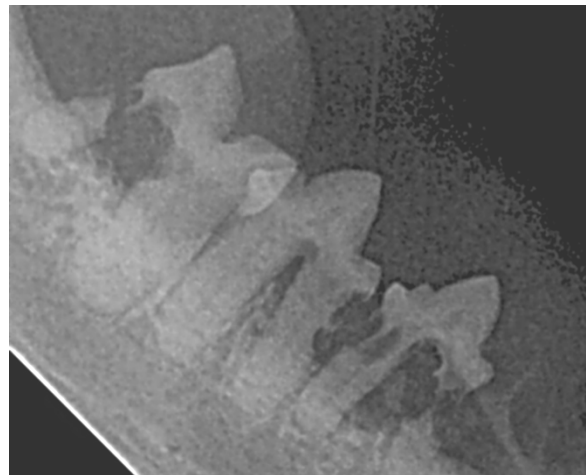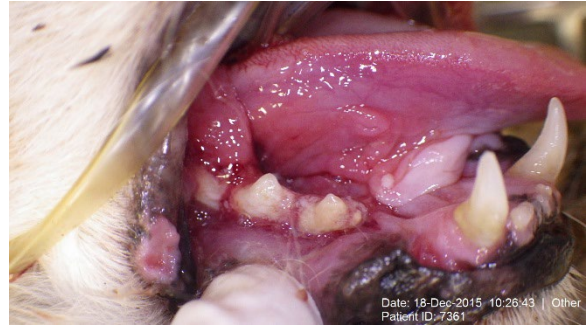The argument I am about to put forward is built on the following foundation:

- The AVMA version of the [Veterinarians Oath](#) states that we "... solemnly swear to use [our] scientific knowledge and skills for the benefit of society through the protection of animal health and welfare, **the prevention and relief of animal suffering,...**".^a
- [Our primary \(dental\) objective](#) for all of our patients must be to provide them with a mouth free of pain and infection.^b Preserving teeth is not the top priority, optimizing oral health is.
- Domestic pet animals have no need for teeth. They do not need to hunt and kill their own food, chew raw flesh from a carcass, defend territory or breeding rights. They do not need teeth but they deserve a mouth free of pain and infection and they enjoy a far happier, healthier life with no teeth than with bad teeth.^b
- As a profession, we (quite rightly) spend a great deal of our time and our clients' money on preventative health care efforts and counselling, because it is well understood that it is far better to prevent serious illness than to treat it. We even do major, life-altering surgery in the interest of preventing problems (spay/neuter, though in many countries in Europe this is banned as it is seen as so life-altering).

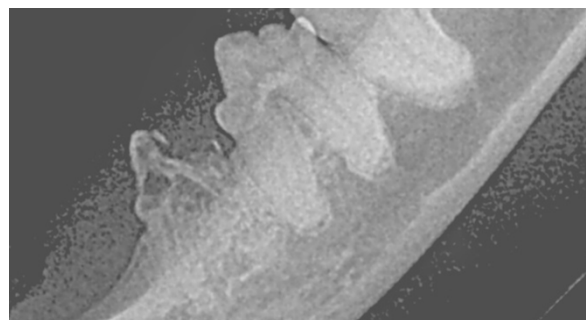
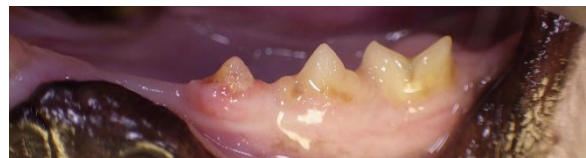Before I go further, I must say that the quality of veterinary dental care being provided, in general, has improved remarkably in the past twenty years and shows every sign of continuing on that positive trajectory. But there is still a very long way to go.

Now let's look at some well-established facts:

- [Tooth resorption in cats](#) is very, very common (if you are not seeing it, you are not looking closely enough) and very painful. We have no certain idea of what causes this and so no means of preventing it. All we can do is wait for it to develop and then extract the affected teeth.^c

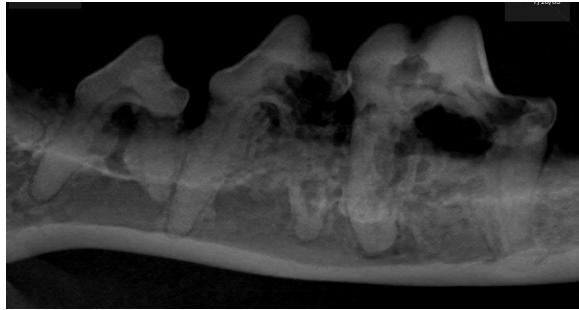

Right mandible of a cat suffering from advanced periodontal disease and type I tooth resorption.



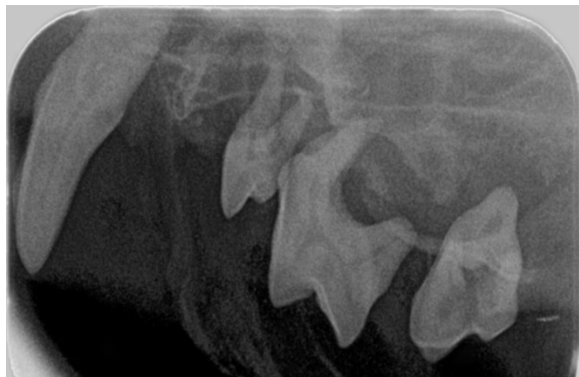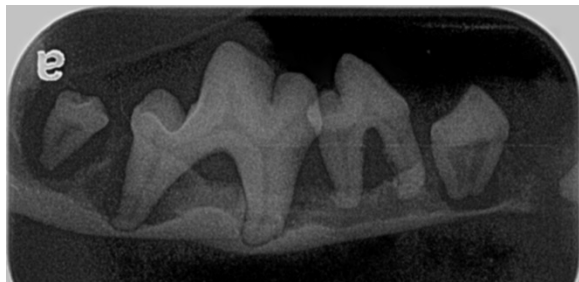Left mandible of a cat with type II tooth resorption affecting the 3rd premolar.

[Tooth resorption is becoming quite common in dogs](#) too and the comments about tooth resorption in cats apply equally to dogs. ^d



Tooth resorption in a dog.

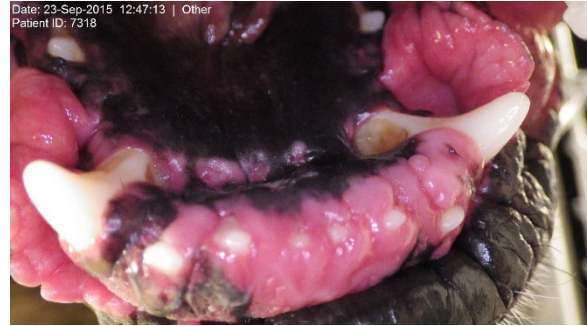Many dogs (highly miniaturized dogs, brachycephalic dogs and especially highly miniaturized brachycephalic dogs) are at extreme anatomic risk for the early development and rapid progression of periodontal disease. While the causes of periodontal disease are known, not nearly enough is done by our profession or pet owners to prevent it. ^{e, f, g, h, i, j, k}



This 8-year-old, 1.4 kg Yorkie had about the worst periodontal disease I have ever seen. There was virtually no mandible left and there were massive oro-nasal fistulae.

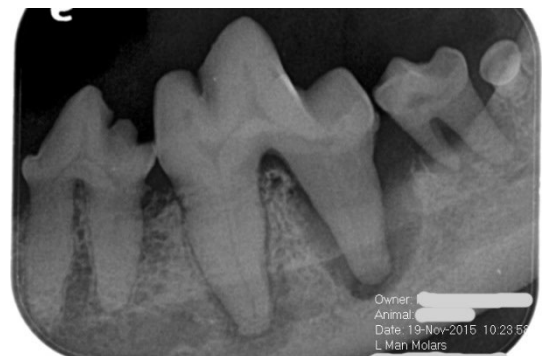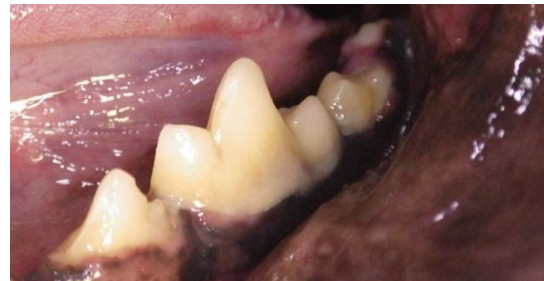Many dogs, and some cats, have serious craniofacial deformities (often dictated by arbitrary breed standards) that result in chronic and painful abnormal tooth-to-tooth and tooth-to-

soft tissue contacts (they bite themselves every time they close their mouth). ^{e, f, g, l, m}



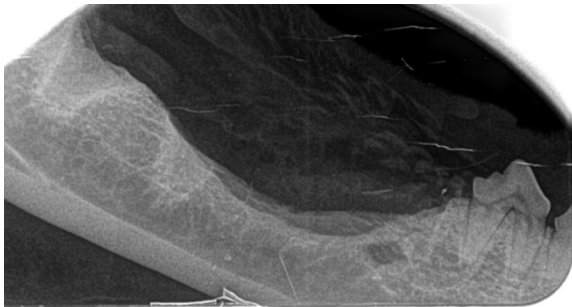
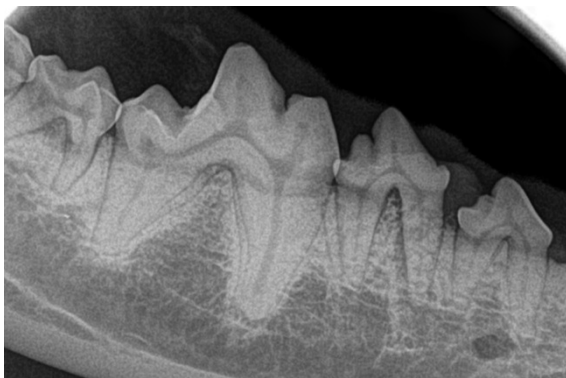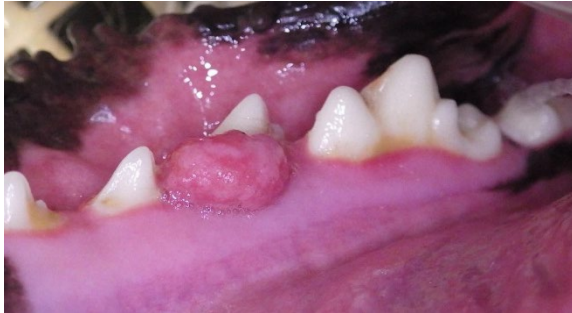This boxer, like all boxers, has a Class III Malocclusion (upper jaw too short) so that the upper incisors have constantly been in traumatic contact with the floor of the mouth and the lingual aspect of the lower canine teeth causing gingival recession and digging holes into the canine tooth roots.

- [Periodontal disease is a largely hidden disease](#) and by the time you see evidence of it on conscious examination, it has been going on for a long time. Also the amount of calculus on the visible portions of the crowns of the teeth is a terrible predictor of periodontal health. ⁿ



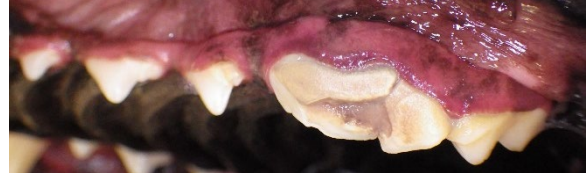The photograph of these lower left molars does not give any real sense of the level of disease depicted in the radiograph. This is a very common finding.

- Many oral growths (benign and malignant) may theoretically be induced by chronic oral inflammation or simply by the dental and parodontal tissues themselves (inductive tumors of dental origin).



Initial biopsy at debulking nine months prior to referral indicated gingival hyperplasia. Assessment of the tissue taken during this Rim Excision indicated squamous cell carcinoma with clean margins.

- Many owners give their dogs ridiculously hard and/or abrasive things to chew on resulting in damage to the teeth which in turn leads to chronic and painful endodontic disease.^{o, p, q}



This five-year-old border collie was given an antler to chew on. Ouch.

- [Dogs and cats will NOT tell you or their owners when they are experiencing dental pain.](#) There are a number of potential reasons for this but it boils down to the fact that they cannot imagine that complaining would improve their lot and in the wild, showing signs of weakness or distress brings bad things so there is a disincentive to complain. And of course they are still eating; because the alternative is....?^r
- [At any given moment, it would be safe to speculate that at least half of your adult canine and feline patients are suffering](#) from some significant (and painful) dental or oral pathology that is going undetected or simply untreated and [virtually all of your brachycephalic patients of any age are already suffering from oral pathology.](#)
- Even your clients that think they are doing something to maintain good oral health are likely not doing nearly enough because:
 - Many owners (and veterinarians) have [unreasonable expectations](#) of what home dental care can achieve, (“Only 33% of dog owners regularly have their pets’ teeth cleaned by a veterinarian, according to Pet Product News. [Instead, many of them are replacing those professional cleanings with treats.](#)”)^{k, s}
 - For any home care product or strategy to be effective it [needs to be applied every day, for life.](#)^o
 - Most products on the market have no valid research to show that they do anything of value,
 - No home care product or strategy (even the very best of them) will treat established disease and any mechanical product or action (diets, chews, tooth brushing) will very likely cause pain when used in a mouth that has pathology.^o

What am I driving at? The title gives you a hint.
Whole mouth extraction for everyone.

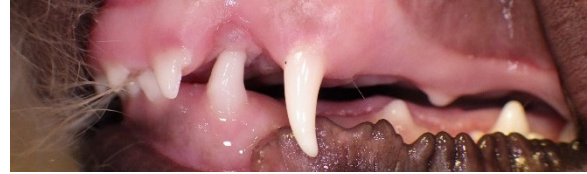Since the current approach is not working at all well I propose (only slightly tongue-in-cheek) that all pet dogs and cats have whole mouth extraction at 6 to 8 months of age. This would, in one procedure, alleviate 100% of all orthodontic and developmental oral issues, prevent 100% of all periodontal disease, 100% of all endodontic disease, 100% of all tooth resorption, likely 100% of [Feline Chronic Gingivostomatitis](#) in cats ¹ and [Contact Mucositis](#) (aka Chronic Ulcerative Parodontal Stomatitis) ¹¹ in dogs and I suspect the vast majority of oral tumors (benign and malignant). We would virtually guarantee that every pet would live its entire life with a mouth free of pain and infection, there would be no concerns about the expense or anesthetic risks in the future and no more battles with owners about how they must start brushing their pet's teeth. Everyone would be *so* much happier. Extracting teeth in these young animals is so much easier than it is once they are a few years old. Extracting healthy teeth is so much easier than extracting those with tooth resorption and ankylosis. Young, healthy animals are a better anesthetic risk and bounce back from major surgery better than a run-down geriatric pet.

After over twenty-seven years of doing nothing but dental and oral surgery, I can see only two alternatives to this prophylactic whole-mouth extraction idea.

I do not want to do whole mouth extractions in young animals. So, what to do instead?

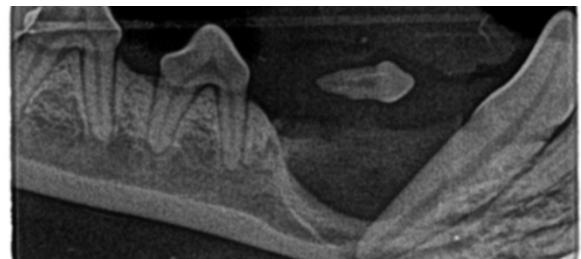
Alternative One, the one I would like to see us all advocate for, is to adopt an approach similar to the one taken by those professionals who care for our oral health but with some modifications for our patients:

- Screening examinations during growth (starting at 8 weeks of age) to monitor for any and all [developmental and structural deformities](#) (especially those deemed “normal for the breed”, which are really “grossly abnormal in accordance with current breed standards”) and appropriate interceptive therapies ^{f,v}



Lingually displaced left mandibular primary canine causing trauma to maxillary tissues. This indicates the need for immediate extraction of the offending primary tooth.

- Between 6 and 8 months of age, a detailed oral examination with whole-mouth intra-oral dental radiographs and appropriate [pro-active therapy](#) to alleviate all tooth-to-tooth and tooth-to-soft tissue contacts, alleviate crowding issues, remove any persistent primary teeth, any [un-erupted](#), seriously [under-erupted](#) or significantly deformed teeth and address areas anatomically predisposed to [caries](#) ^{e,w,x}



This unerupted lower right first premolar resulted in the development of a large dentigerous cyst which destroyed the bone support for the lower canine tooth.

- Warn emphatically against the use of hard or abrasive toys and treats that are inclined to cause serious dental damage (natural and nylon bones, antlers, cow hooves, large raw hides, tennis balls...) ^{o,p}
- Warn emphatically against games and vices (tug of war, fence chewing...) that are known to cause dental damage
- Immediately after healing from any proactive surgeries, establish a safe and effective daily home plaque control program using VOHC accepted products and tooth brushing, warning against the use of untested/unproven products regardless of how aggressively they are marketed and ensuring owners have reasonable expectations for the program ^{s,y}

- No matter how clean the crowns seem to be on conscious examination, annual anesthetized dental examinations and maintenance therapy for as long as the pet has teeth (following the [AAHA Dental Care Guidelines for Dogs and Cats](#))^z
- Educate the clients regarding what to look for between annual professional examinations that might indicate the need for immediate action (growths, fractures, changes to the oral odour or appearance of the oral tissues...)
- Educate and advocate against the propagation of highly miniaturized and brachycephalic animals

While that approach will not prevent all dental disease (as I mentioned, we have no idea how to prevent tooth resorption in dogs or cats), it will certainly help a great many animals enjoy good oral health for the majority of their time on earth. Much disease will be prevented and what does develop will be found and treated sooner than later reducing the days of suffering.

Alternative two is the status quo, in which animals suffer in silence for much of their lives from painful oral pathology, losing a few teeth every now and then until eventually they are all gone and then they finally get to enjoy a mouth free of pain and infection for their last few years/months. Or more commonly, they carry oral pathology to their grave, never knowing the joy of a mouth truly free of pain and infection. [We do a lot of [whole-mouth extractions](#) in mature pets because by the time they get referred to me, there is no other rational alternative.]^{aa}

- https://en.wikipedia.org/wiki/Veterinarian%27s_Oath
- http://www.toothvet.ca/PDFfiles/Things_I_tell_clients.pdf
- http://www.toothvet.ca/PDFfiles/Tooth_resorption_in_cats.pdf
- http://www.toothvet.ca/PDFfiles/RLs_in_Dogs.pdf
- <http://www.toothvet.ca/PDFfiles/microdogs.pdf>
- http://www.toothvet.ca/PDFfiles/Stop_Brachy.pdf
- <http://www.toothvet.ca/PDFfiles/FocusOnBoxers.pdf>
- <http://www.toothvet.ca/PDFfiles/PerioComm.pdf>
- <http://www.toothvet.ca/PDFfiles/PerioAgain.pdf>
- <http://www.toothvet.ca/PDFfiles/pericoronitis.pdf>
- <http://www.aaha.org/blog/NewStat/post/2015/12/09/129937/Professional-pet-oral-care-still-an-educational-challenge.aspx>
- http://www.toothvet.ca/PDFfiles/Feline_Gum_Chewer.pdf
- http://www.toothvet.ca/PDFfiles/briggs_occlusion.pdf
- http://www.toothvet.ca/PDFfiles/perio_hidden.pdf
- <http://www.toothvet.ca/PDFfiles/HomeCarePack.pdf>
- http://www.toothvet.ca/PDFfiles/no_bones.pdf
- <http://www.toothvet.ca/PDFfiles/endo.pdf>
- <http://www.toothvet.ca/PDFfiles/mythology.pdf>
- http://www.toothvet.ca/PDFfiles/reasonable_expectations.pdf
- <http://www.toothvet.ca/PDFfiles/fcgs.pdf>
- <http://www.toothvet.ca/PDFfiles/cups.pdf>
- <http://www.toothvet.ca/PDFfiles/juvenilecusp.pdf>
- <http://www.toothvet.ca/PDFfiles/proactive.pdf>
- <http://www.toothvet.ca/PDFfiles/DentalCaries.pdf>
- http://www.toothvet.ca/PDFfiles/VOHC_SEAL.pdf
- http://www.toothvet.ca/PDFfiles/aaha_dental_guidelines_2019.pdf
- http://www.toothvet.ca/PDFfiles/WME_part_2.pdf