

HALE VETERINARY CLINIC

Fraser Hale, DVM, FAVD, DiplAVDC

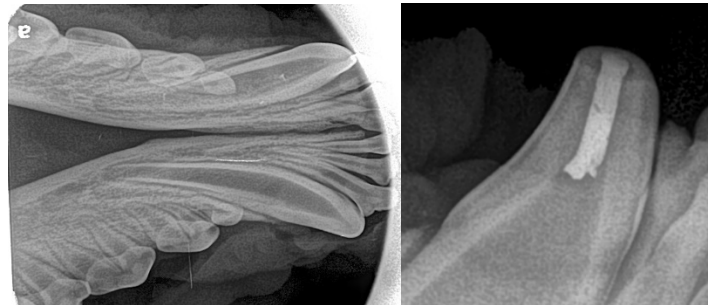
BOARD-CERTIFIED
VETERINARY DENTIST™

DENTAL AND ORAL SURGERY FOR PETS SINCE 1991

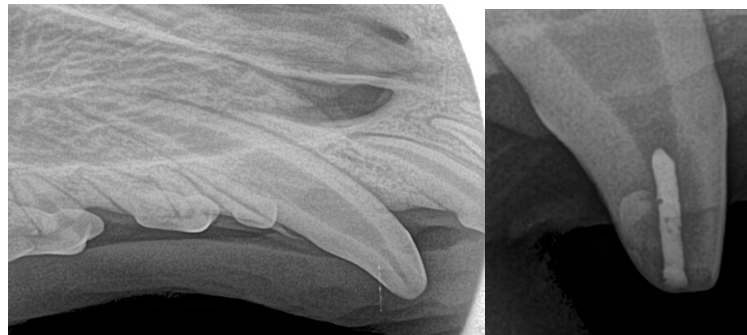
Regarding Follow-up Radiographs to Assess Response to Vital Pulp Therapy

For dogs that have had vital pulp therapy (either electively to manage a malocclusion or as an emergency treatment of a recently fractured immature tooth), it is important to obtain follow-up radiographs several months (6 to 12 depending on various factors) post-operatively to monitor the status of the pulp inside the teeth. As the primary care veterinarian for a dog that has undergone vital pulp therapy, we are asking if you would be able to obtain the necessary images and send them to me for assessment. There are some very specific images I need, as outlined below.

For dogs that have had vital pulp therapy of one or both lower canine teeth, I need an image of the rostral mandible that shows both lower canine roots symmetrically for side-by-side comparison and including several millimeters beyond the root tips. And I need a lateral view of the crown of the treated tooth/teeth.



For dogs that have had vital pulp therapy of an upper canine tooth, I will need images of the full root and tissue beyond the treated tooth and the contralateral canine for comparison and a lateral view of the treated crown.



Photographs of the treated tooth/teeth and restoration(s) and (for dog who had crown reduction for malocclusion), photographs of the areas of previous palatal trauma would also be great.

If you have any questions about this, please contact us for clarification before anesthetizing the patient.

Regards,

Fraser Hale, DVM, FAVD, DiplAVDC

Information on emergency vital pulp therapy (to treat fractured teeth in young animals) - <http://www.toothvet.ca/PDFfiles/Pulpotomy.pdf>

Information on elective vital pulp therapy (for management of a malocclusion) - <http://www.toothvet.ca/PDFfiles/CrownReduction.pdf>

PHONE

519-822-8598

FAX

519-763-6210

EMAIL

info@toothvet.ca

WEB SITE

www.toothvet.ca

ADDRESS

159 Fife Road,
Guelph, ON N1H-7N8

OFFERING

ROUTINE AND ADVANCED

VETERINARY DENTAL SERVICES

IN THE FOLLOWING AREAS

ENDODONTICS

ORAL MEDICINE

ORAL SURGERY

ORAL & DENTAL RADIOLOGY

ORTHODONTICS

PERIODONTICS

PROSTHODONTICS

RESTORATIONS

Hale Veterinary

Professional Corporation