

## PERIODONTAL DISEASE – AGAIN

I have discussed periodontal disease and the challenges of detecting and managing it in the past ([PerioCommon.pdf](#) and [perio\\_hidden.pdf](#)) and several other papers at [Old CUSP Articles](#).

Regardless, deciding when to institute a periodontal treatment program still poses a challenge for a number of reasons.

For many owners, the cost of professional periodontal evaluation and treatment may be a deterrent. For many others, the fear of general anesthesia is a major hurdle to overcome. Those obstacles notwithstanding, few owners, if properly informed, would opt for a “wait ‘til they are rotten and then extract” approach to oral care. But because periodontal disease is hidden from view (not only in the mouth, but also below the gum line) it can be hard to know when there is going to be sufficient benefit from treatment to justify the attendant cost/risk.

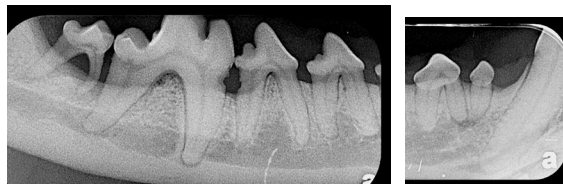This week I saw two animals who were under-treated for several years and as a result, required many extractions that I suspect could well have been prevented with more aggressive care from a much earlier age. They were by no means unique cases, as I see such examples every week, but one in particular troubled me in the way our profession let the owners and their pet down.

I should point out that it is not the loss of the teeth that troubles me most. I have said on a great many occasions and feel strongly that domestic dogs and cats do not need teeth. What they need and deserve is a mouth free from pain and infection. What bothers me most about these cases is that by the time I see them and they need extensive exodontia due to end-stage periodontal disease, they have been living with chronic oral pain and infection for many months if not years.

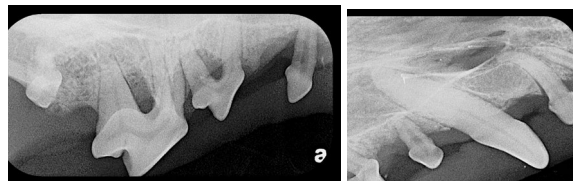
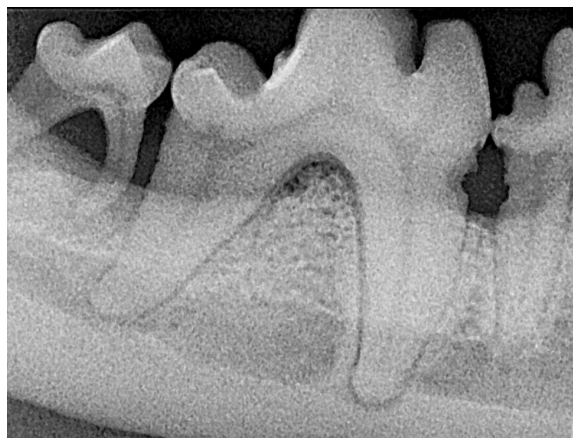
The illustrative case in question was a seven year old Bichon Frise. He had had his first professional dental treatment (not by me) about a year before I saw him at which time some (undisclosed) teeth were extracted. The owners had been brushing daily but were concerned by the foul odour and bleeding during brushing so they sought us out.

Conscious examination revealed clean crowns but obvious indications of deep and advanced

periodontal disease (gingival recession, tooth mobility). I too noted the nasty oral odour. It was apparent that this patient was going to need a great many more extractions. I did not take any photographs in his mouth but the radiographs are quite demonstrative of the problems.



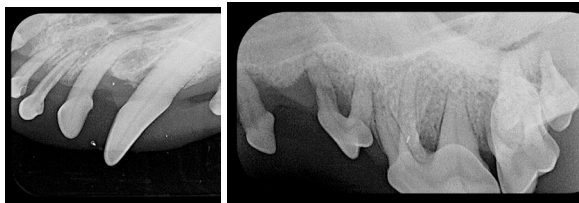
The two images above of the right mandible show that the 3<sup>rd</sup> molar is missing, the 2<sup>nd</sup> molar has end-stage periodontal disease and there is significant disease affecting the 1<sup>st</sup> molar and 4<sup>th</sup> premolar. In the close-up below, we can see bone loss down the distal root of the 1<sup>st</sup> molar. Then on the mesial aspect of the mesial root of the molar and the distal aspect of the distal root of the 4<sup>th</sup> premolar, there are subgingival defects in the roots – either inflammatory root resorption or root caries ([DentalCaries.pdf](#)) as well as bone loss between these teeth.



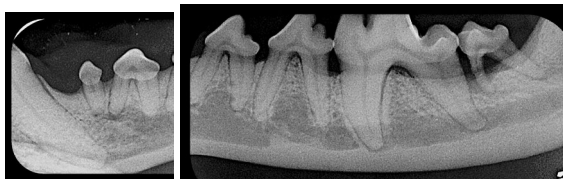The images above of the right maxilla show advanced periodontal disease with grade 3 furcation exposure of the 2<sup>nd</sup> and 4<sup>th</sup> premolars and end-stage disease (over 50% bone loss) of the 1<sup>st</sup> premolar. While not radiographically apparent, the 2<sup>nd</sup> molar was grade 3 of 3 mobile.

Also note the size of the pulp chambers in the 1<sup>st</sup> premolar and the 2<sup>nd</sup> incisor. Those pulp chambers are way too big for a seven year old dog and noticeably larger than the rest of the dog's teeth. This tells us that the pulp in these teeth died many years ago. Have a look at this to review what I mean about the pulp chamber size issue: [endo.pdf](#).

Next we have the left maxilla with advanced periodontal disease of all but the canine tooth and pulp necrosis in the 2<sup>nd</sup> incisor. The canine does have an infra-bony pocket, but is still a tooth worth trying to save.



The left mandibular teeth were similar to the right. The 1<sup>st</sup> molar, in different circumstances, might have been worth treating but since all the upper premolars and molars were coming out, there was no point.



The patient had arrived already missing 11 teeth and I extracted another 19. The remaining 12 were scaled and polished above and below the gum line and some periodontal surgery was done for the pocket on the palatal side of the left upper canine tooth.

The take-home message I am trying to get across here is that there is no way a Bichon Frise, or any small dog, or really any dog or cat of any shape, size or breed, should get to be six years old before it has its first detailed dental examination and treatment. By waiting until there are obvious signs of disease on a quick, conscious oral examination before prescribing action you will ensure that a great many of your patients will suffer in silence for years with undiagnosed disease and that when you do finally treat, many situations will be beyond repair.

My recommendation is that every pet have a thorough oral inventory done by eight months of

age. An excellent time to do this would be at spay/neuter if this is being done around six months of age. This gives an opportunity to look for and address the many developmental problems that so many of our patients have such as:

- persistent primary teeth
- impacted/unerupted adult teeth
- deformed adult teeth
- malocclusion with abnormal tooth-to-tooth or tooth-to-soft tissue contacts
- crowding
- under-eruption.

Several of those problems will have an impact on the periodontal future for the patient. Under-eruption can lead to [pericoronitis](#). Crowding can result in food entrapment and plaque retention predisposing to periodontal disease. All of these early developmental problems should all be documented and addressed. This involves removing all primary teeth and any impacted/unerupted adult teeth. Teeth involved in malocclusions may be removed, moved or reshaped (those last two likely involve referral). Selective extraction of crowded teeth is indicated to reduce the crowding and improve the periodontal prognosis for the teeth left in. Crown lengthening surgery is indicated for under-erupted teeth.

These pro-active measures are intended, not necessarily to make the mouth normal, because for a great many of our patients that simply is not possible. Look at the skeletal craniofacial architecture of any brachycephalic dog or cat, compared to what nature intended, and you will see that 'normal' is not an option. These animals have serious skeletal deformities imposed on them by selective breeding driven by human desires and fashion dictates, not by natural selection of what works best for the animal. I do not even like to use the term 'normal', as in, "it is normal for a pug to have a short face." It may be breed-standard, but it is in no way normal – it is a deformity that is considered desirable by the owner but that comes with significant costs to the pet (the poor things can hardly breathe). Our job is to minimize the costs to the pet of having been put together that way. So my approach is to 'make the best of a bad design'.

For some excellent photos of the skulls of various breeds go to [www.skullsunlimited.com](http://www.skullsunlimited.com) and view their catalogue. You will notice great similarities between the skull shapes and occlusal relationships among the wild canids and felids and that many of our domestic pet breeds represent a significant departure from these natural forms. These unnatural head shapes anatomically predispose to problems, including periodontal disease.

Following the first dental evaluation and treatment to deal with the developmental problems and a week or two for healing, it is time to institute a daily home care program. While more and more products are coming on the market all the time to aid in this regard, many of them are not worth the box they come in. On the other hand, there are some worthwhile products, but even the best of them are nothing more than an **aid** in the **prevention** of disease *for use in a clean healthy mouth*. None of them are in the slightest effective in treating established disease and none of them should be considered a substitute for daily brushing and regular professional dental care.

This lengthy document - [HomeCarePack.pdf](#) – outlines several home care concepts, discusses a few products and classifications of products. It finishes up with the two-page home care sheet we send home with clients that outlines the training program to get their pets to enjoy and demand daily tooth brushing.

The Veterinary Oral Health Council was established to develop standard protocols for evaluation of efficacy of products with a dental claim and then reviews research done by the manufacturer. If the product has demonstrated a benefit then it is awarded the VOHC Seal of Acceptance. A complete list of accepted products can be found at [www.vohc.org](http://www.vohc.org). Note that some products have been awarded the seal based on their ability to help control tartar (calculus) and others have the seal for their ability to help control tartar and plaque. Since plaque is the primary concern, products with the plaque control designation would be valued more highly than ones with the tartar designation alone.

If you have done the spay/neuter dental evaluation and treatment and the owners have instituted a good home dental program, when

should you plan to re-anesthetize for the next detailed dental examination and treatment? It is a valid question but one that is hard to answer with certainty.

I like to put it in terms my clients can relate to. I tell them that I brush my own teeth twice a day, floss daily and still see my dentist and hygienist every 9 months. While I enjoy good oral hygiene and periodontal health, they always find some areas to clean that I have been unable to reach with the brush and floss.

If the owners have been brushing their pet's teeth, the visible portions of the crowns should look clean and shiny but the hard-to-see areas (between teeth, the back teeth, the lingual/palatal aspects and below the gum line) are also the areas that are harder for the owner to reach with the brush. So you cannot rely on visual inspection of the easy-to-see portions of the crowns for evaluation of dental health. You need to anesthetize to examine and clean those hidden areas – and of course, to do whole-mouth dental radiographs to look for other problems such as root fracture, [tooth resorption](#) and endodontic disease. The general recommendation is that this be done on an annual basis. This allows for a much more preventative approach rather than a crisis-management approach.

I believe that if the Bichon in the example had received annual professional dental evaluations and treatments from an early age as well as the home care the owner had been providing, he would have been spared years of chronic periodontal infection. Because the owners had been brushing the teeth, the crowns looked pretty good and so it did not appear that there was any need for professional dental care and there lies the problem. Periodontal disease is hidden from view in the conscious patient. We must anesthetize and go looking for it if we are going to prevent it or catch it early when it can be treated effectively.

**All brachycephalic animals have significant skeletal deformities affecting their oral health and need our help to make the best of a bad design.**