

Management of Fractured Primary Teeth in Puppies

It is not uncommon for puppies to suffer fracture to one or more of their primary teeth and the question often arises, “What do we need to do about these injuries?” The answer is, **fractured primary teeth require immediate, complete and careful extraction.** Read on to find out why.

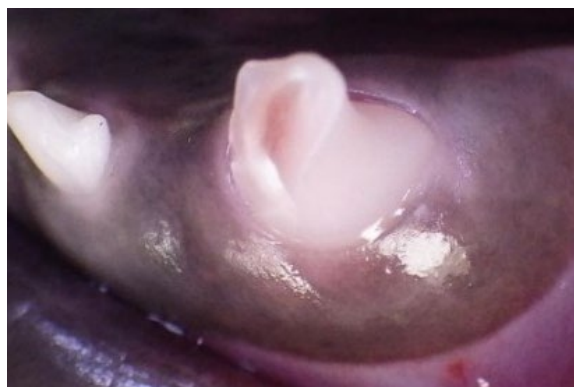

Fig. 1. A fractured lower left primary canine tooth in a puppy. There is obvious exposure of the dental pulp (the soft tissue inside the tooth) evident in this image.

Primary teeth are the baby teeth, also known as deciduous or milk teeth. They erupt when the pup is 4 to 8 weeks of age and should all have fallen out, to be replaced with the adult (permanent, secondary) teeth by about 6 months of age. The most commonly fractured primary teeth (by far) are the canine (fang) teeth (Fig. 1) and we will be looking mostly at examples of that in this paper. However, the principles apply equally to all primary teeth in puppies, and in kittens for that matter.

The term *endodontic* refers to anything going on with the dental pulp (soft tissue inside the tooth) and the diseases and treatment of the pulp and in the space around the tip of the root(s) of the tooth.

Let's start with the understanding that **ALL** teeth with pulp exposure require either endodontic treatment or extraction and many teeth with damage that has not obviously exposed the pulp also need treatment. For more on why this is so, you can view these other papers from my website:

[Endodontic Anatomy and Physiology](#)

[Vital Pulp Therapy vs Total Pulpectomy](#)

[What is Root Canal Treatment?](#)

[Uncomplicated Crown Fractures](#)

[Endodontic Diagnosis](#)

Also, Myths #1 and #2 in [Dental Mythology](#)

Rather than making you read through all of those now, here is the a synopsis of the anatomy of teeth and why teeth with endodontic disease require treatment.

Basic Anatomy of a Tooth

Each tooth (primary or adult) is made of four tissues. There is a thin layer of hard, non-porous *enamel* covering the crown (visible portion) of the tooth (about 0.5 mms thick for adult teeth and more like 0.25 mms thick for primary teeth). The root of the tooth is covered by a thinner layer of *cementum*. Under the enamel of the crown and the cementum of the root is the main hard tissue of the tooth, *dentin*. Dentin is harder than bone but, not as hard as enamel and it is porous, being full of microscopic holes that go right through, known as *dentin tubules*. Inside all of this hard tissue is the hollow space which contains the soft tissue of the tooth known as the *dental pulp* (blood vessels, nerves and other soft tissues).

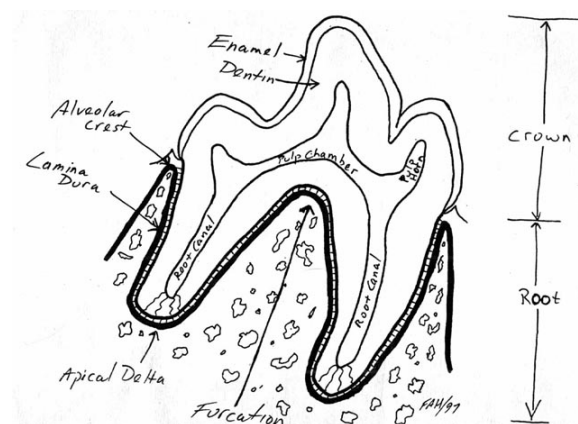


Fig. 2. A line drawing of a mature, adult tooth. The cementum covering the roots of this tooth is not labelled in this diagram, but it is there.

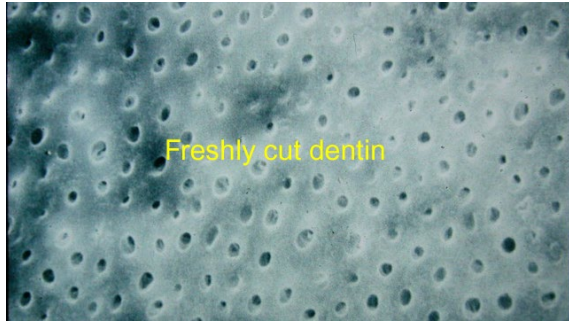


Fig. 3. Freshly cut dentin showing its porous nature (dentin tubules).

When a tooth first erupts it has all the enamel it will ever have (enamel is all formed prior to eruption of the tooth) but has a very thin dentin wall and a massive pulp chamber. Once the tooth had erupted fully, cells lining the inside of the dentin wall produce more dentin so that over time, the pulp chamber gets smaller as the dentin wall gets thicker.

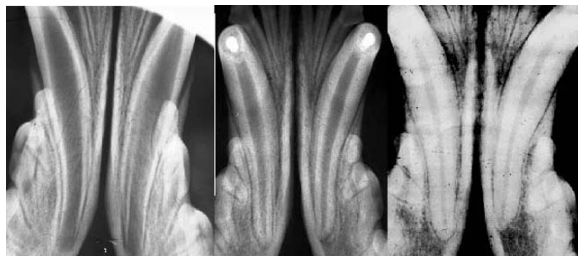

Fig. 4. Radiographs of the lower canine teeth taken of the same dog at (from left to right) 6 months, 14 months and 32 months of age. Note how the pulp chamber (dark space inside the tooth) gets smaller as the hard (white) dentin wall gets thicker over time.

Normally, the only way into or out of the pulp chamber of a healthy, intact tooth is through a collection of tiny channels at the root tip known as the *apical delta*. When the tooth first erupts, the end of the root is wide open with no apical delta (see the 6-month radiograph in Fig. 4) As

If the primary teeth are programmed to fall out on their own, why can we not just leave them alone to do that? Why do they require careful, complete, and immediate extraction? Lots of reasons. Read on.

the tooth matures, the delta forms and its channels get narrower as more dentin is laid down.

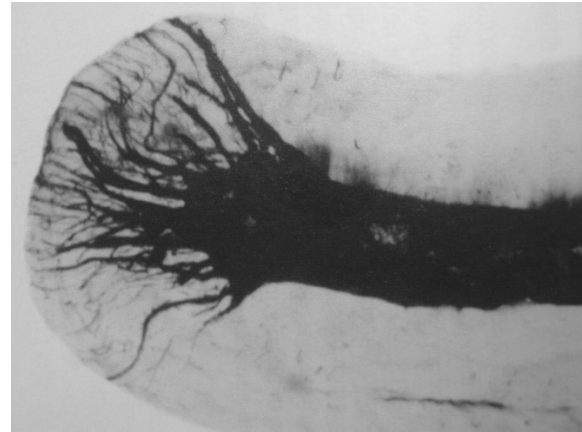

Fig 5. Photograph of an apical delta, highlighted with India Ink.

Consequences of Tooth Fracture

The most straightforward scenario to start with is a tooth that suffers a fracture (or abrasive wear) that exposes the dental pulp (a *complicated crown fracture*). In this example, what happens next (in the absence of appropriate and timely treatment) is completely inevitable and predictable though the time that it takes for each thing to happen can be quite variable.

1. The exposed pulp quickly becomes contaminated with oral bacteria
2. The pulp undergoes septic inflammation
3. The pulp undergoes septic pulp necrosis (dies)
4. The bacteria can now ooze out through the root tip to cause septic inflammation in the space around the root tip and eventually in the bone itself (*apical periodontitis*). The tooth is effectively a hollow tube embedded in the jaw bone and open to all the bacteria in the animal's mouth.
5. Untreated, the chronic infection around the tip of the tooth root will be a constant source of pain and can lead to destruction of the surrounding bone and/or the root

tip, can lead to open draining tracts and/or infection of the soft tissues of the face (*facial cellulitis*).

In the case where a tooth is worn or fractured in a way that does not expose the pulp directly but does expose the porous dentin (an *uncomplicated crown fracture*), the tooth might suffer the same fate as in a complicated crown fracture, as it is possible for bacteria to pass through the dentin tubules to contaminate and kill the pulp... But not all teeth with dentin exposure go on to develop endodontic disease as I mentioned in that paper linked on page 1 about uncomplicated crown fractures.

So, ALL adult teeth with endodontic disease require endodontic treatment (vital pulp therapy or full root canal treatment) or extraction. That is just the facts, Jack. But we are talking about primary teeth in this paper, so let's move on to them.

Issues Specific to Primary Teeth

As with the adult teeth, when primary teeth erupt, they have all of their enamel (though it is a very thin layer) but a thin dentin wall and a massive pulp chamber. Since primary teeth have a life-span of only a few months (are not present at birth and should be all gone by 6 months of age), they do not have time to produce a thick dentin wall before they exfoliate (fall out). So, all primary teeth in puppies (and kittens) have very thin dentin walls, very large pulp chambers and quite open root tips (no solid apical delta or a delta with relatively large channels).

The thin delicate nature of the primary teeth predisposes them to traumatic fracture. The fact that they are in the mouths of busy, curious and clumsy puppies (and kittens) increases the risk. So does the misguided notion that puppies should be given hard things to chew on or that playing tug-of-war is a good idea.

While the crowns of the primary teeth are visible in the mouth, the adult teeth are busy developing down (or up) inside the bones of the mouth and

can be seen below or adjacent to the root tips of the primary teeth.

These issues are all evident in the following three dental radiographs.

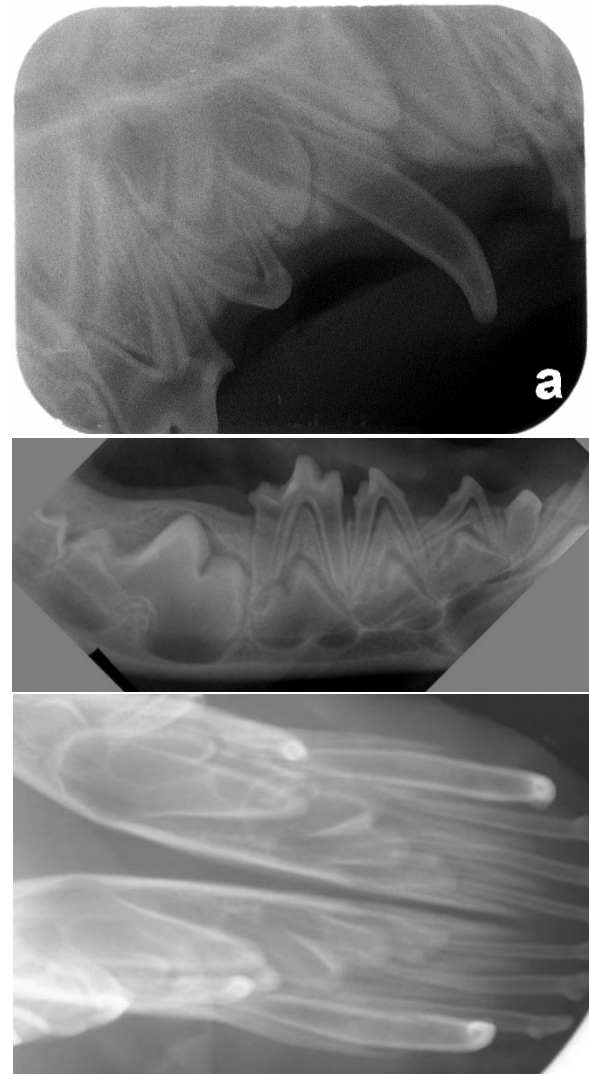


Fig. 6. From top to bottom, radiographs of the right rostral maxilla, right mid mandible and rostral mandibles of young puppies, showing some of the primary teeth in place and the developing adult tooth buds below the surface. Note how thin-walled the primary teeth are and the wide open root tips.

Another issue that plays into this subject is that the jaw bones of these young animals is relatively thin and soft (compared to in a mature animal). You will see why that is important soon.

Fractured Primary Teeth

If a primary tooth suffers a fracture with pulp exposure, the pulp will become contaminated, then infected. The pulp will die and then the infection will ooze out through the root tip(s) to set up an apical periodontitis. This is all painful for the animal, whether they express this in a way the owner perceives or not.

The apical periodontitis (septic inflammation around the tip of the root of the tooth) can result in destruction of the thin, soft bone overlying the root so now the infection is into the soft tissues of the mouth resulting in a facial cellulitis. This may result in a localized swelling as in Fig. 7 or a full-blown facial swelling as in Fig. 8.

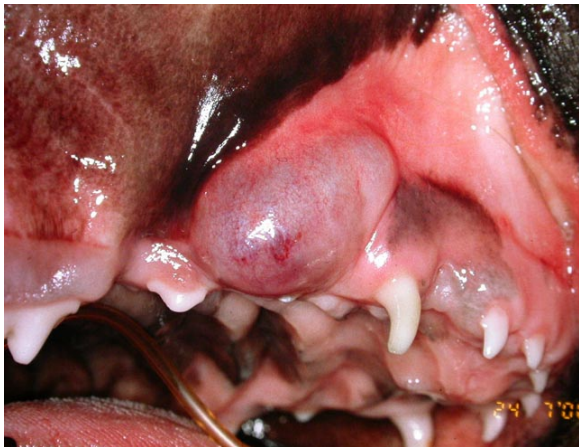

Fig. 7. A localized facial cellulitis secondary to infection resulting from damage to the tip of the right upper primary canine tooth.

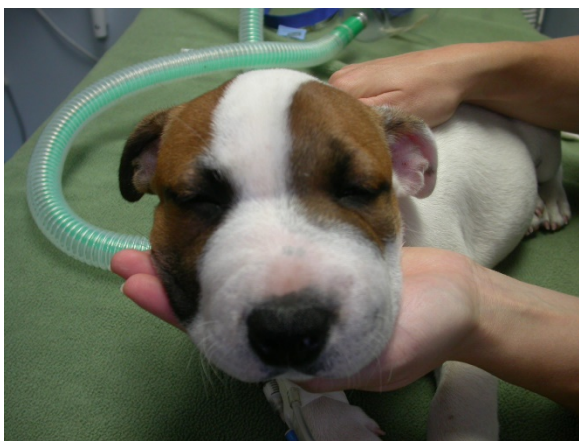

Fig. 8. Generalized facial cellulitis that developed secondary to fractures of both upper primary canine teeth (Fig. 9.)

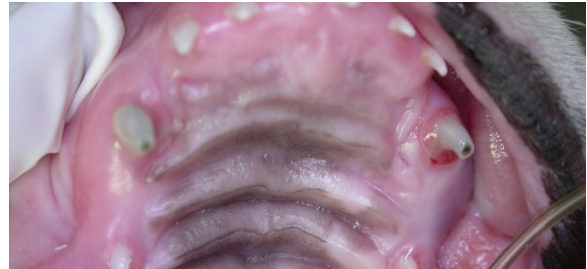

Fig. 9. Fractures with pulp exposure and necrosis of both upper primary canine teeth.

Another possible outcome is that the infection/inflammation, having eaten through the bone, continues and breaks through the soft tissue to create a draining *fistulous tract*, also known as a *parulis* as seen in Fig. 10.

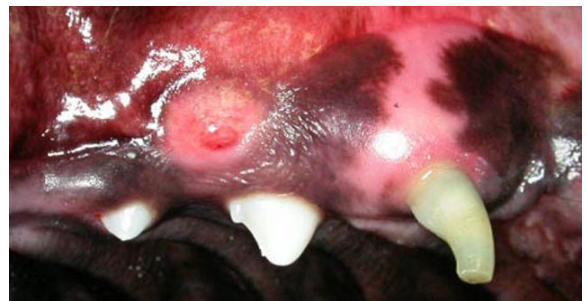

Fig. 10. A parulis over the tip of the root of the fractured and dead/infected right upper primary canine tooth.

We occasionally get the question, since primary teeth are expected to fall out on their own, why do we need to extract fractured primary teeth? Why can we not just wait for them to fall out on their own? Well, the fractured tooth and the infection/inflammation that results is certainly painful and it is not medically acceptable to leave a painful situation untreated. By the Veterinarian's Oath, we are sworn to use our scientific knowledge and skills for...the prevention and relief of animal suffering. Therefore, ignoring fractured teeth (primary or adult) is counter to the oath we swore when we became veterinarians. Sometimes these primary teeth are broken months before they would be

expected to fall out and leaving the pet in pain for that time is not acceptable. Also...

As well as the pain associated with pulp exposure, necrosis, apical periodontitis and facial cellulitis, there are other potential consequences of leaving these fractured primary teeth in place.

- The inflammation associated with the apical periodontitis can cause damage to the tissues trying to form the adult teeth resulting in permanent developmental defects of the adult teeth in the region of the root tip of the fractured primary tooth.
- There have been reported cases of puppies developing tetanus secondary to fractured primary teeth.
- The inflammation around the root may prevent the primary tooth from falling out on schedule (more on this below).
- The inflammation around the infected root might cause the overlying gum tissue to die (more below).

Persistent Primary Teeth

The primary teeth are supposed to fall out to make room for and be replaced by the adult teeth. For that to happen, the body absorbs the roots of the primary teeth and when there is no root structure left, the crowns fall out. Recall when you were a child and your primary teeth fell out, all you had to leave under the pillow was the crown of the tooth, with no root.

I have found, on several occasions, that fractured, necrotic and infected primary teeth have not fallen out as they should. It seems as if the inflammation around the root interferes with the normal process of physiologic root resorption that would allow the primary tooth to vacate the mouth.

If the primary tooth remains in place while the adult tooth is erupting, it forces the adult tooth into an abnormal location as discussed in my paper on [malocclusions](#). For example, when the upper primary canine remains in place, it forces the adult tooth to erupt too far forward in the

mouth which can block the space where the crown of the lower adult canine tooth is supposed to go.

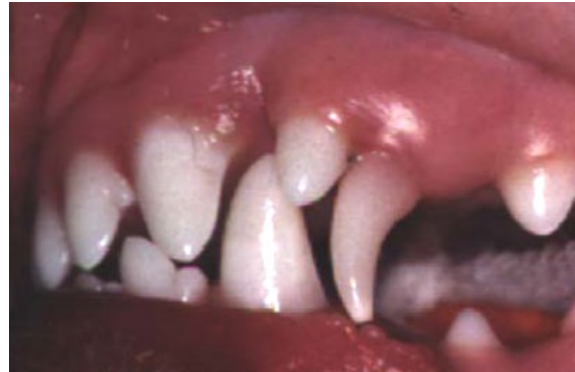

Fig. 11. A persistent (not broken) left upper primary canine tooth forcing the upper adult canine tooth to erupt too far forward, closing the space where the lower adult canine tooth crown is supposed to go.

If the lower primary canine tooth remains too long, it forces the lower adult canine tooth to erupt “lingually displaced) so that it points up at and then contacts/traumatizes the roof of the mouth.

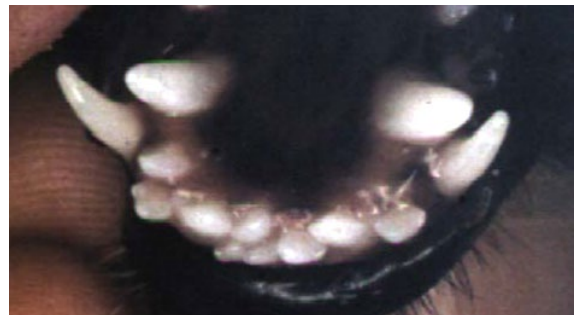


Fig. 12. Persistent (though not broken) lower primary canine teeth forcing the lower adult canine teeth to erupt lingually displaced putting them on a path to contact and traumatize the roof of the mouth.

If a fractured, necrotic, infected primary canine tooth is not extracted, there can be several negative (and avoidable) consequences.

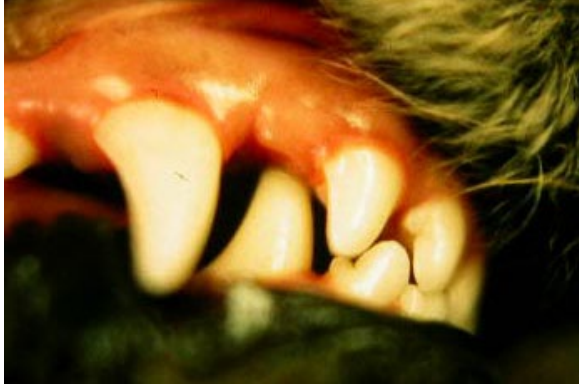

Fig. 13. A lingually displaced lower right adult canine tooth digging a hole in the roof of the mouth.

Gingival Clefts/Sloughing

To see the significance of this next issue, you need to know something of normal periodontal anatomy and the importance of a complete and healthy gingival collar surrounding each tooth. I go into this in some detail in this [video](#). The short answer is that each tooth requires a complete gingival collar around its entire circumference and if there is a breach in this collar, the tooth has no future and requires either extraction or advanced periodontal surgery (grafting) to re-establish that complete collar.

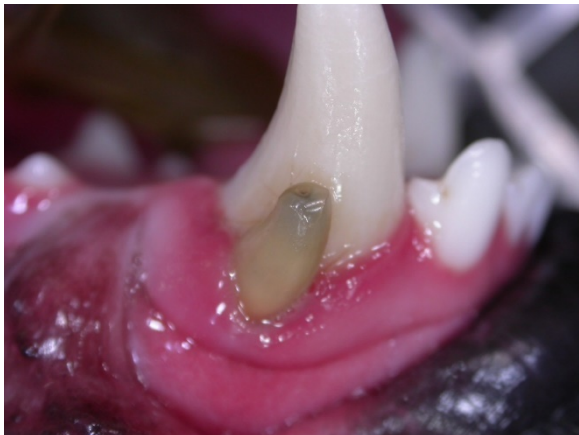

Fig. 14. A fractured, dead, infected and persistent lower right primary canine tooth not only forcing the adult tooth to erupt lingually displaced but also resulting in a significant cleft in the gingiva, compromising the periodontal health of the adult canine tooth.

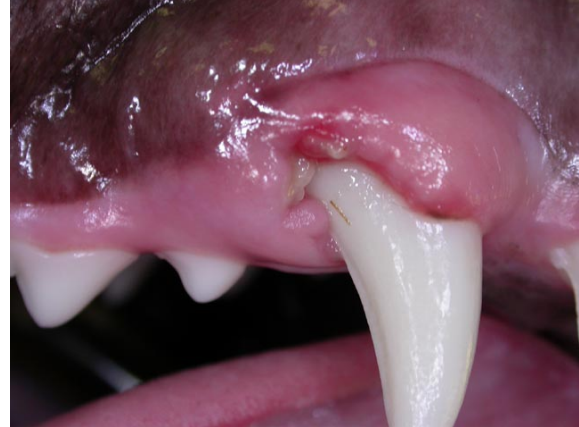

Fig. 15. In this case, there were retained remnants of the roots of the fractured and necrotic right upper primary canine tooth resulting in a significant gingival cleft over the right upper adult canine tooth.

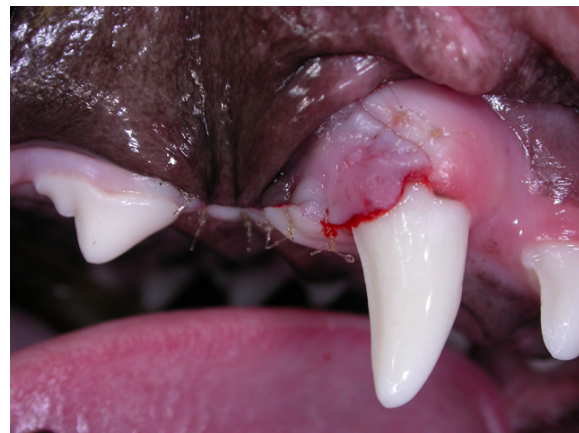

Fig. 16. This photograph of the same animal was taken after sacrificing the 1st adult premolar and swinging a gingival graft forward to close the cleft and give the adult canine tooth a chance.

Caution

I believe I have established that fractured primary canine teeth require immediate, complete and careful extraction.

Immediate to alleviate the suffering and prevent further negative consequences.

Complete to ensure no fragments of contaminated root are left behind to act as ongoing sources of infection/inflammation and negative consequences.

Careful because:

- the adult teeth are developing right next to the roots of the primary teeth and great care must be taken to avoid damaging those developing adult teeth.
- The primary tooth roots are very long, thin-walled and delicate and may be partially resorbed, making them even more delicate, so it can be challenging to get the tooth out without the root fragmenting and if it does fragment, all the fragments need to be removed.

Many consider extraction of primary teeth to be “[NFCO](#)” (not for the casual operator). It is beyond the scope of this paper to discuss the technique for removing primary teeth. If you are not comfortable taking on this delicate procedure, you should refer.

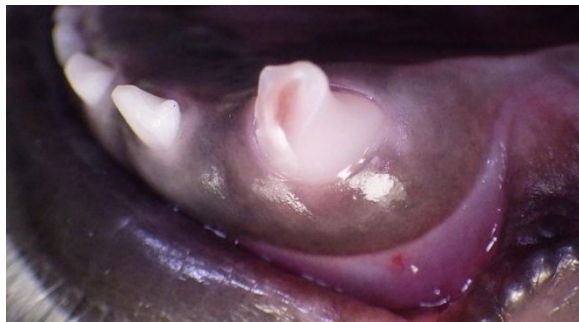

Fig 17. Actually Fig. 1 again. A fractured lower left primary canine tooth with pulp exposure.

As with all dental work, intra-oral dental radiographs are absolutely essential for the proper pre-op assessment and documentation of the situation and for post-op documentation of the results of the procedure. Clinics not currently incorporating intra-oral dental radiography for each and every dental procedure are strongly encouraged to make that change immediately. You really should make the time to watch my 40-minute video presentation on this.

[Why intra-oral dental radiographs are essential.](#)

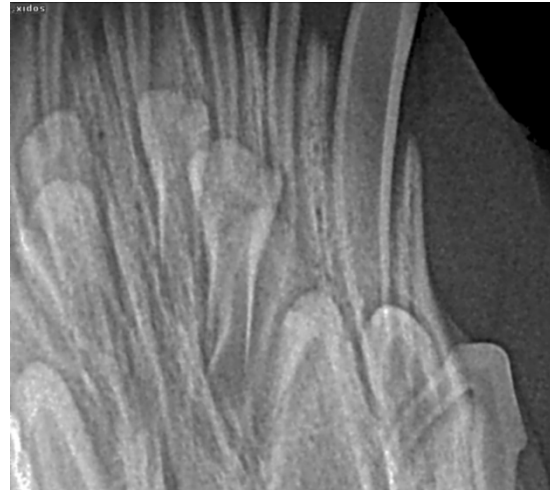


Fig. 18. The required pre-op intra-oral dental radiograph.

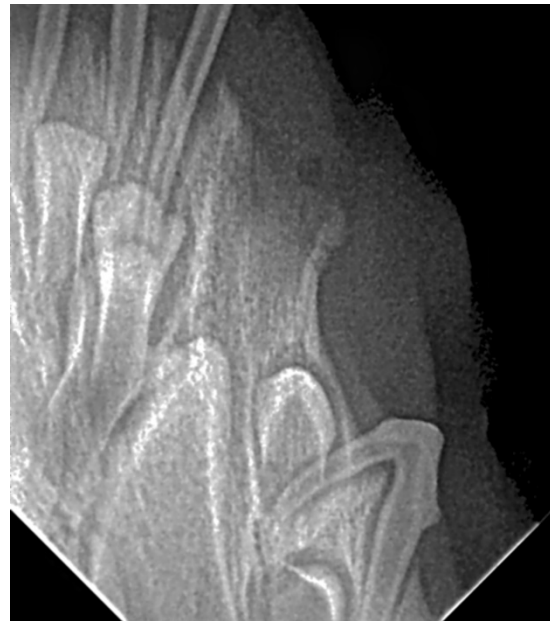


Fig 19. The required post-op radiograph.

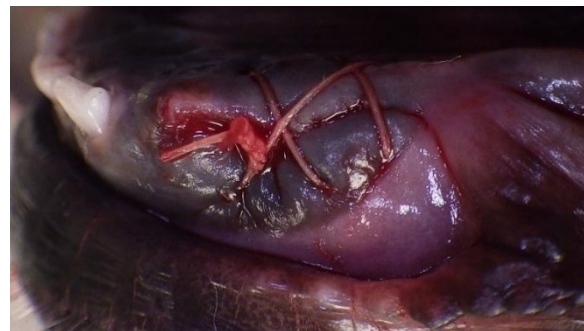

Fig. 20. Site closed with absorbable suture material.