

# Dental Crowding and its Effect on Periodontal Health

I have touched on this subject in the past in other papers (for example, [perio\\_hidden\\_microdogs](#), [Brachy\\_issues](#)). In this paper I want to look at it in a bit more detail with some specific recommendations. However, to understand why dental crowding leads to an increased risk for the development of periodontal disease, one must know about desirable periodontal anatomy, the relationships between the various tissues and how periodontal disease develops and progresses. So, for a refresher, I recommend you watch this 26 minute video - [Periodontal video](#) and/or review this (older) paper - [PerioAnat&Physio](#).

Teeth with the inherently best defence against periodontal disease are the ones with a complete, uninterrupted collar of attached gingiva around their entire circumference. In Figure 1, that would include (from right to left), the canine tooth, the 1<sup>st</sup>, 2<sup>nd</sup> and 3<sup>rd</sup> premolar teeth. These teeth all have sufficient space between themselves and their adjacent neighbours to have a complete gingival collar. In this dog, the distal aspect of the 4<sup>th</sup> premolar is in tight contact with the mesial aspect of the 1<sup>st</sup> molar and then the distal aspect of the 1<sup>st</sup> molar is in tight contact with the mesial aspect of the 2<sup>nd</sup> molar. Those areas of tight contact are at increased risk for the development of periodontal disease, even in this large, mesaticephalic dog (Labrador retriever).

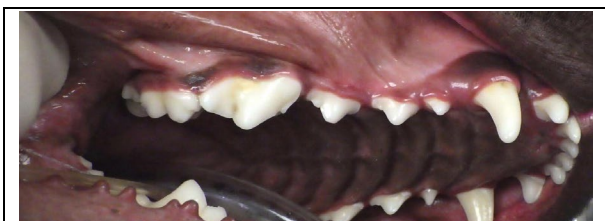


Figure 1: Good, dental spacing for canines and first three premolars. Tight contacts between molars and 4<sup>th</sup> premolar.

Some dogs even enjoy good spacing between the maxillary molars and 4<sup>th</sup> premolar as in Figure 2, but this is not as common.

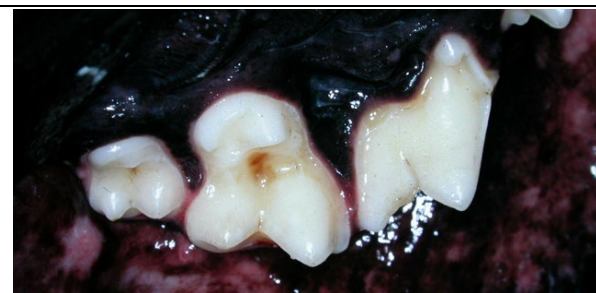

Figure 2. Palatal view of the left upper (from left to right) 2nd molar, 1st molar and 4th premolar showing desirable spacing with complete gingival collars around each tooth.

Even in large, mesaticephalic dogs, there tends to be relatively tight contacts between the back teeth (4<sup>th</sup> premolar and all molars) in both upper and lower jaws. These spaces do not always develop periodontal disease, but they are at higher risk (see Figure 3 on the next page).

What I really want to talk about, however, are a few specific locations of significant dental crowding very common to micro-dogs that can and should be alleviated in a proactive manner at a very early age.

It has been well established that the teeth of small dogs are proportionally much larger than the teeth of larger dogs (see figure 4 on the next page). All dogs, regardless of size, are supposed to have the same number of teeth (42 teeth to be exact). What this means is that the smaller the dog, the more dental crowding there is. Even small dogs lucky enough to have the congenital absence of some teeth may still have insufficient room for the teeth they do have. The crowding frequently means a lack of gingiva between adjacent teeth and this is a foot-in-the-door for periodontal disease to get established and progress early and rapidly.

While we cannot make small dogs larger or their teeth smaller, we can reduce the number of teeth in the mouth to alleviate crowding issues and improve the periodontal prognosis for the teeth left in place. This selective “weeding of the oral garden” is something that needs to be done before

periodontal disease gets started. I like to do it well before the animal's first birthday.

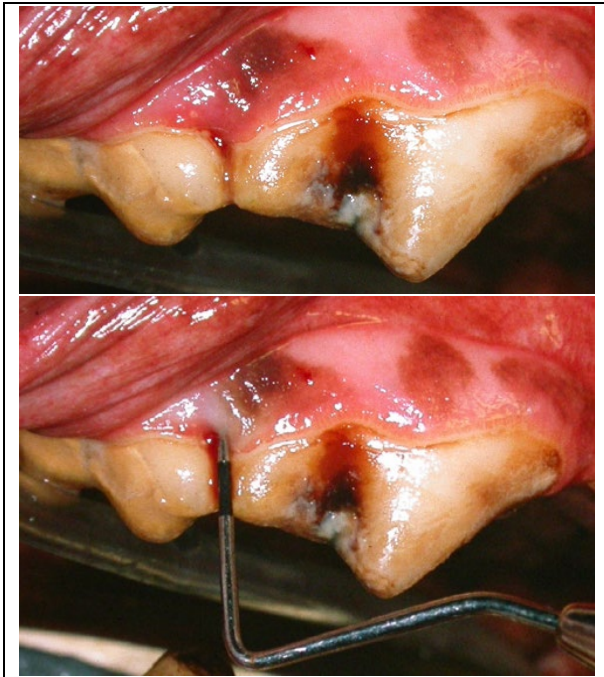


Figure 3. While the top clinical photo shows the tight contact between the mesial aspect of the 1st molar and the distal aspect of the 4th premolar, it does not really hint that there is any trouble associated with this. The bottom image shows a periodontal probe inserted into a hidden 8-mm deep periodontal pocket between these two large and important teeth.

When deciding which teeth to remove, I use the analogy of looking at the mouth like a chess board. We are going to sacrifice the pawns to protect the bishops/knights/kings/queens. In other words, if there are two teeth jammed tight against each other, remove the smaller, less important one to improve the prospects for the larger, more important one.

There are three locations that I find are the most commonly in need of this approach.

#### 1. Third and Fourth Upper Premolar Teeth.

The upper 4<sup>th</sup> premolar tooth is the largest and most important of the upper chewing teeth. It is a high-value tooth and we should do all we can to protect it. The 3<sup>rd</sup> premolar, by contrast, is much smaller and less important.

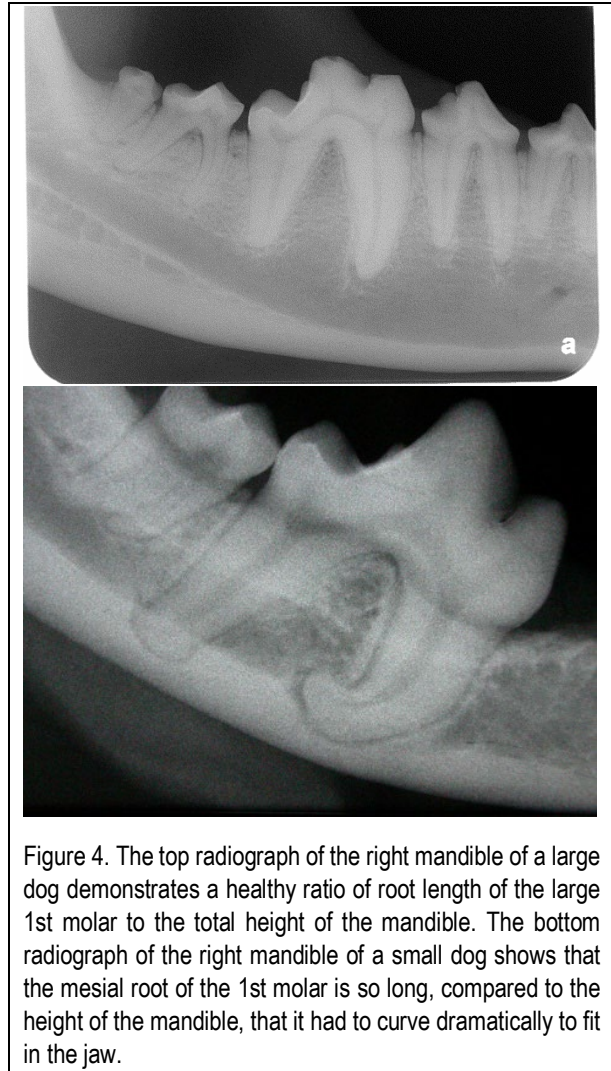

Figure 4. The top radiograph of the right mandible of a large dog demonstrates a healthy ratio of root length of the large 1st molar to the total height of the mandible. The bottom radiograph of the right mandible of a small dog shows that the mesial root of the 1st molar is so long, compared to the height of the mandible, that it had to curve dramatically to fit in the jaw.

The 4<sup>th</sup> premolar tooth has three roots; one at the back and two at the front. Therefore, at the mesial aspect of the tooth (front), there is a space where the mesiobuccal and palatal roots head off in their own directions and this spot is known as the mesial furcation (Figure 5 on next page).

In small dogs, it is common for the distal aspect of the 3<sup>rd</sup> premolar to be jammed into that mesial furcation of the 4<sup>th</sup> premolar and this puts both teeth at high risk for developing periodontal disease in this location.

The dog in Figures 6 to 8 was a 4-year-old, 3.8 kg male, neutered chihuahua mix being seen for his first detailed dental assessment. Figure 6 is the clinical photograph of the crowding in which you can see the distal aspect of the 3<sup>rd</sup> premolar

nestled all snug up in the mesial furcation of the 4<sup>th</sup> premolar. Figure 7 is the radiograph of that area and really shows how the distal aspect of the 3<sup>rd</sup> premolar was trapped in that space.

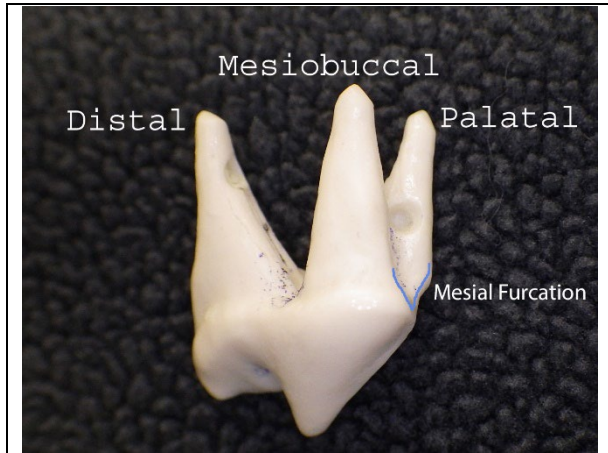


Figure 5. A plastic model of the right upper 4<sup>th</sup> premolar tooth showing the mesial furcation (blue line).

dried cortical bone of canine origin and closed the wound.

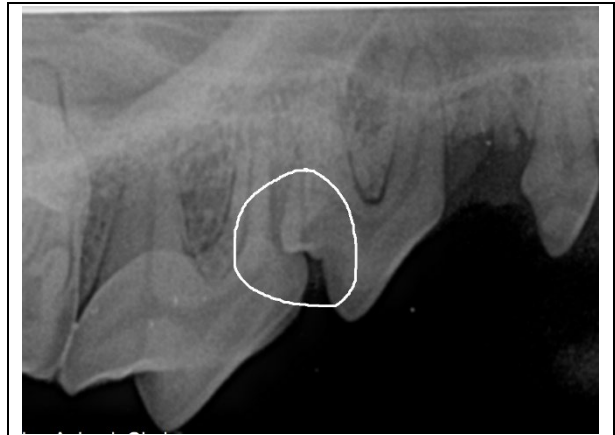


Figure 7. In the radiograph, you can see how the distal shoulder of the 3<sup>rd</sup> premolar is trapped in the mesial furcation of the 4<sup>th</sup> premolar. What other abnormalities do you see in this radiograph? (answer on last page).

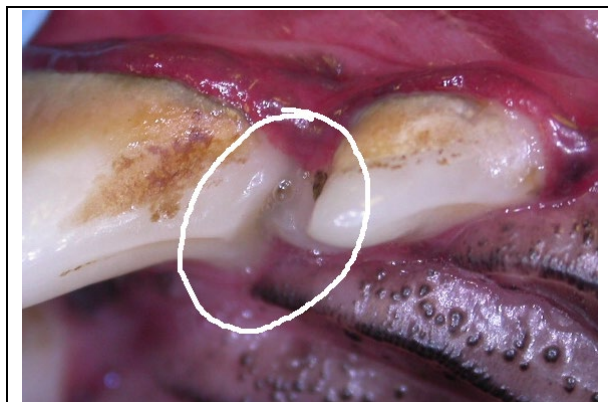

Figure 6. Clinical photograph of the distal aspect of the 3<sup>rd</sup> premolar jammed tight into the mesial furcation of the 4<sup>th</sup> premolar. You can see that there is no gingiva between these two teeth but there does seem to be some pus oozing from below the surface at that point of contact.

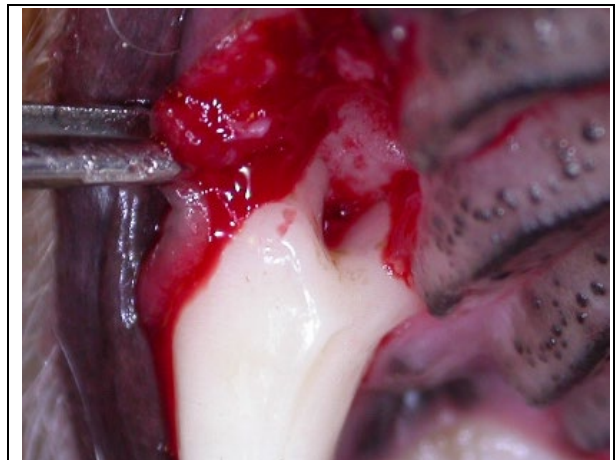


Figure 8. After removing the 3<sup>rd</sup> premolar, the extent of the periodontal disease invading the mesial furcation of the 4<sup>th</sup> premolar was evident. There is bone loss deep into the space between the roots.

Figure 8 is a photograph taken after the removal of the 3<sup>rd</sup> premolar so we have a clear view of the mesial furcation of the 4<sup>th</sup> premolar with bone loss deep into that space. This constituted quite significant periodontal disease and I was close to deeming the 4<sup>th</sup> premolar tooth beyond hope, in which case I would have had to extract it as well. After a frank discussion with the owner, we opted to give this tooth a chance, so I thoroughly debrided the furcation, placed a graft of freeze-

While I had hoped to see the dog for follow-up assessment and maintenance therapy the following year, it was actually nearly four years before I saw him again (owner had been out of province). I am pleased to report that the defect had healed very well and was maintaining in a normal and healthy state. Probing depths were normal and there was no furcation exposure or calculus below the gum line.

I might mention that the situation was (as it usually is) bilaterally symmetrical. While it worked out for this little guy and he did end up retaining the form and function of his important upper 4<sup>th</sup> premolar teeth, it was a close call.

***To prevent the loss of both the 3<sup>rd</sup> and 4<sup>th</sup> upper premolar teeth due to periodontal disease secondary to crowding, I recommend extraction of the smaller, less important 3<sup>rd</sup> premolar and wound closure to provide a brighter future for the larger, more important 4<sup>th</sup> premolar tooth.***

## 2. First and Second Upper Molar Teeth

In micro-dogs, the upper 2<sup>nd</sup> molar is a pretty tiny tooth with very short roots and very little bone support. It is also of quite limited functional value. Add to that, it is often jammed right up tight against the distal aspect of the larger, more valuable 1<sup>st</sup> molar such that there is no gum tissue between them and maybe no bone either. This is another site of dental crowding that puts both teeth involved at a much higher risk for the development of periodontal disease. The treatment, again, is to remove the smaller, less important tooth (2<sup>nd</sup> molar) and close the wound to improve the periodontal prospects for the larger, more important 2<sup>nd</sup> molar.

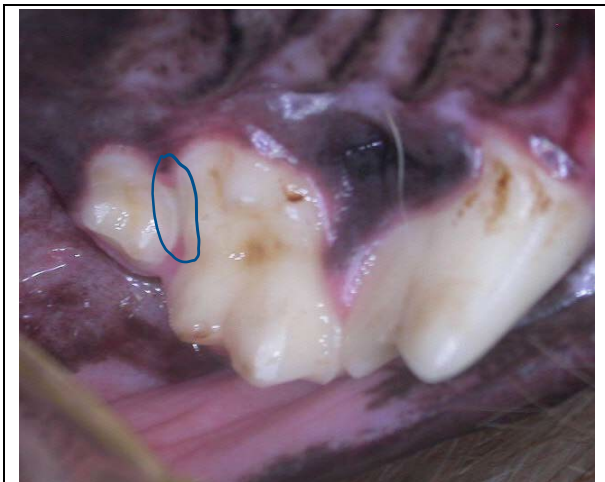


Figure 9. Palatal view of the upper 2<sup>nd</sup> and 1<sup>st</sup> molars and 4<sup>th</sup> premolar with the oval around the area of tight contact and periodontal liability between the molars in a Yorkie.

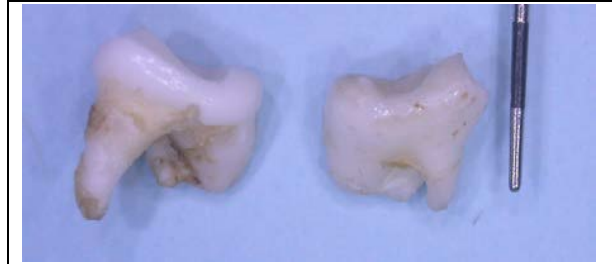


Figure 10. The extracted upper 2<sup>nd</sup> molars from a tea-cup poodle. Some of these roots are less than 3-mm long.

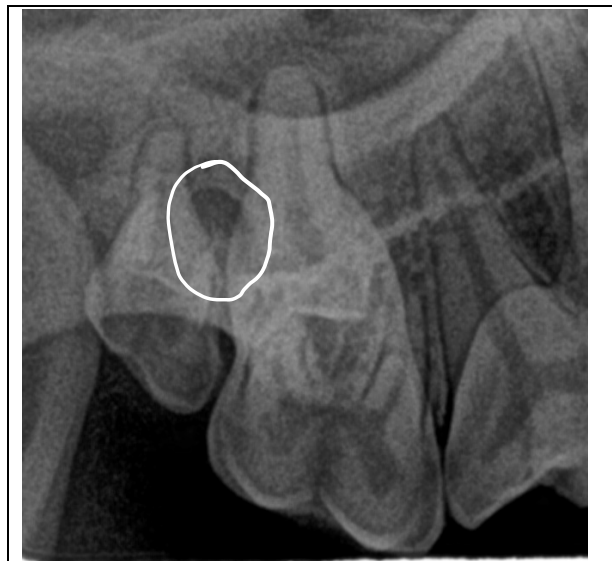

Figure 11. Circle around an area of bone loss between the 2<sup>nd</sup> and 1<sup>st</sup> upper right molars in a 2-yr-old, 4.4 kg miniature dachshund. The 2<sup>nd</sup> molar was extracted in the hope of halting progressing of disease and allowing this dog to keep her 1<sup>st</sup> molar for many more years.

## 3. Lower Third Incisor and Canine Teeth

The third common location for crowding to be an issue is between the lower 3<sup>rd</sup> incisor and lower canine tooth. This is the most extreme example of a small, low-value tooth (lower 3<sup>rd</sup> incisor) being a real liability to a large, high-value tooth (the lower canine tooth). The lower canine teeth are important for helping a dog keep its tongue in its mouth, so it is worth expending considerable effort to keep them healthy.

In small dogs, there is typically crowding of all of the lower canine and incisor teeth but the most problematic spot is between the 3<sup>rd</sup> incisor and

canine. There is usually no gingiva between them and may not even be any bone separating the incisor root from the canine root. Periodontal disease can quickly get down between these two, not only putting the incisor beyond hope but also really compromising the future of the canine teeth.

As you might guess, the recommendation is to pro-actively remove the 3<sup>rd</sup> incisor and close the wound to improve the periodontal prospects for the larger, far more important canine tooth.

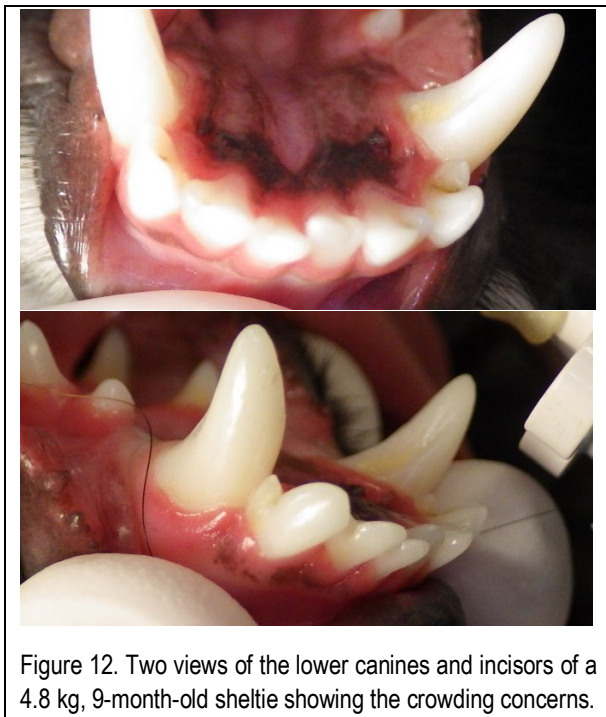


Figure 12. Two views of the lower canines and incisors of a 4.8 kg, 9-month-old sheltie showing the crowding concerns.

### Conclusion

I have outlined the three sites where I most commonly extract a small tooth to improve the future for a larger tooth. Every case must be assessed on its own merits to decide if selective extraction is warranted in those sites. It is also important to examine the entire set of teeth as there may be other areas of crowding that call for pro-active intervention. I highly recommend that every micro-dog have a detailed assessment at 6-7 months of age to look for and alleviate their crowding issues (as well as the other common micro-dog problems such as persistent primary teeth, unerupted teeth, deformed teeth...).

For those animals who fall through the cracks and did not get that early evaluation, when you do get a chance to do their first [COHAT](#), be on the lookout for signs of trouble everywhere but particularly in areas of crowding and even if there is no disease yet, consider some “weeding of the garden” to improve the prospects for maintaining good oral health.

[Daily home plaque control](#) is also essential for maintaining good oral health.

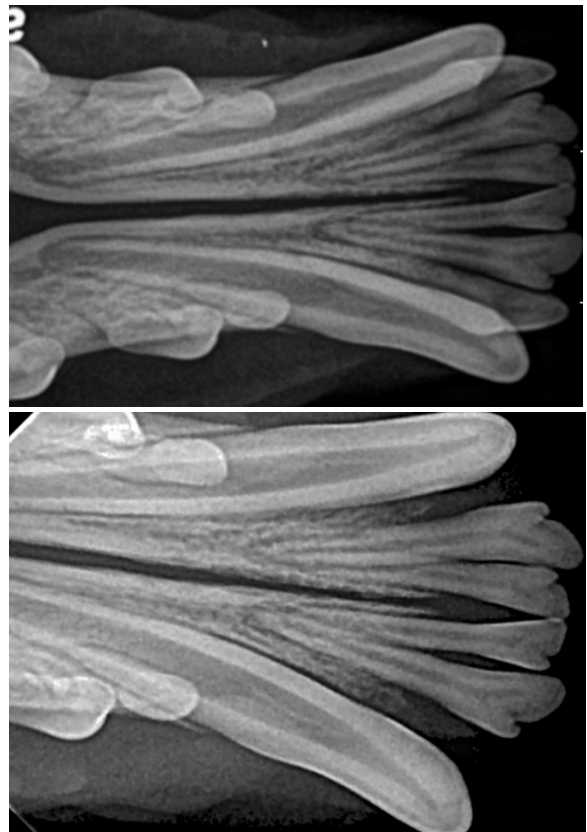


Figure 13. Before and after radiographs of the sheltie in Figure 12. After removing the 3<sup>rd</sup> incisors, the canines have a much better chance of staying healthy.

\* Figure 7 not only showed the crowding between the 3<sup>rd</sup> and 4<sup>th</sup> premolars. It also documented the absence of the adult 2<sup>nd</sup> premolar and the persistence of the mesial root of the primary 2<sup>nd</sup> premolar and that retained root required removal.