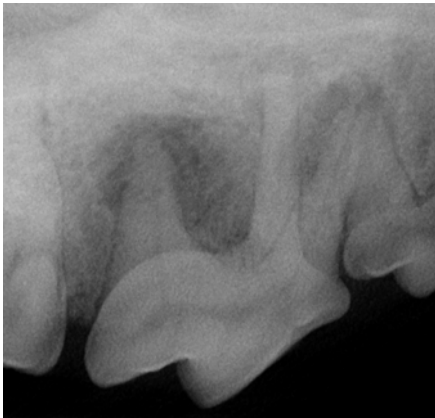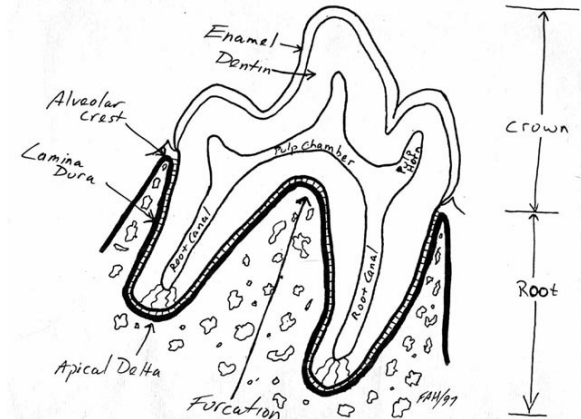


THE CHEVRON SIGN

In the last issue of The CUSP, I discussed radiographic and optical indications of endodontic disease in www.toothvet.ca/PDFfiles/endo_dx.pdf. One of the important radiographic signs of endodontic disease is the periapical lucency. In the radiograph below of the right maxillary fourth premolar tooth in a dog we see very obvious periapical (around the root tips) radiolucencies (areas of decreased density). These dark halos around the root tips are definite signs of inflammation which almost certainly stems from endodontic disease (septic pulp necrosis). When you see lesions as obvious as this, you know this is a chronic problem. There has to be a lot of bone loss before there is enough contrast for it to show up radiographically. Therefore, it is possible to have a tooth with endodontic disease and inflammation around the root tips that still looks perfectly normal radiographically because there has not yet been enough bone loss to show up on the image.

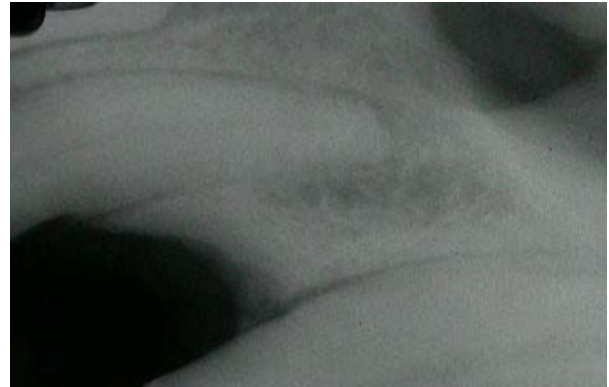

The other thing we look for is an increase in the width of the periodontal ligament space around the root tip and/or loss of the lamina dura. This is an earlier sign of periapical inflammation than the large lucencies above and it is also open to much more interpretation.



In my drawing above, you can see the periodontal ligament space is a consistent width around the entirety of both roots. Radiographically it shows up as a thin dark line between root and bone. The lamina dura is a thin layer of dense cortical bone that lines the socket and shows up radiographically as a thin white (dense) line.

As well as having false negatives (the tooth has serious endodontic disease but there is no radiographic evidence of this yet), there can be false positives and for the dental-radiograph-newbie, these can be quite confusing. It has been observed that many perfectly healthy teeth may have an increase in the periapical periodontal ligament space or an apical lucency as part of the normal anatomic variation. These findings have been termed (at least for now) chevron artifacts. They are not really artifacts as they are true radiographic features of the actual anatomy but the term chevron refers to the shape of these lucencies particularly when they are associated with the maxillary canine teeth.



The image above is of the root and surrounding bone of the left upper third incisor tooth in a dog. There is an area around the root tip that is obviously less dense than much of the other bone in the region but this is perfectly normal. The incisive bone is very dense near the top of the socket and between the incisor roots but beyond that it becomes spongy, cancellous bone so the decrease in radiodensity is just the normal variation in bone density in the various regions of the incisive bone. If you follow the periodontal ligament space around this root, you will see that it is clear and evident around the entire root.

From this point on you may be wondering what I am talking about. Partially it will depend on the quality of the monitor you are using to view the images. Partially it will depend on your eyesight. Either way, I will acknowledge that some of the changes I am describing here are quite subtle and that is why they can be difficult to interpret.

The next radiograph is of the apex of the right upper canine tooth in a dog. There seems to be an area of decreased bone density at the apex. The tooth was clinically normal and there was no reason to suspect endodontic disease. The left canine tooth looked the same. Therefore, it was assessed as the chevron sign. A year later the same tooth looked basically unchanged except that the pulp chamber has gotten smaller (indicating continued normal pulp activity).

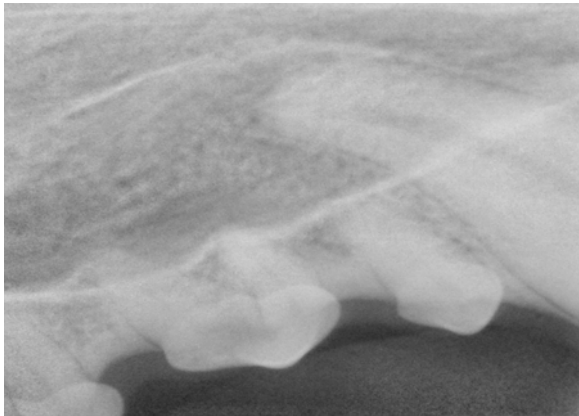


Image captured with an EVA-Vet direct digital sensor.


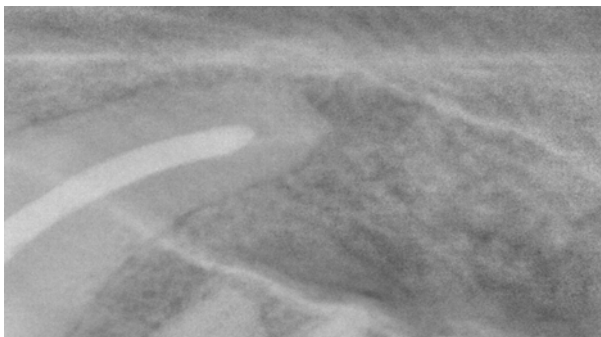
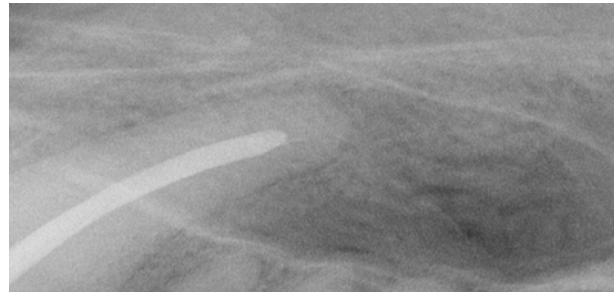


Image captured using the ScanX indirect digital system.

On the other hand, the lucency in the film below was assessed as a true periapical lesion indicative of periapical periodontitis of endodontic origin and so root canal treatment was performed.



And a year later, the lesion had healed.



This next image is from the same dog and is of the right mandibular first molar.

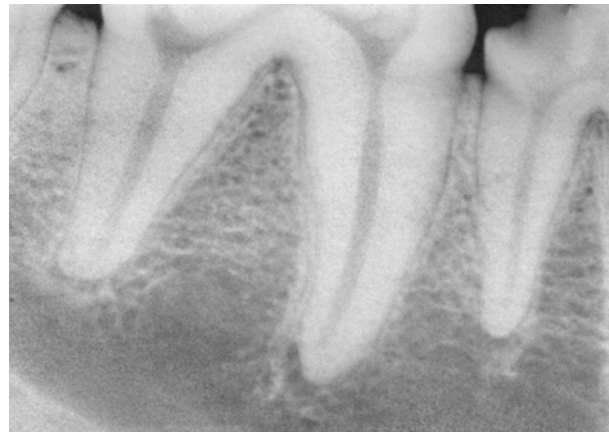


Image captured with an EVA-Vet direct digital sensor.

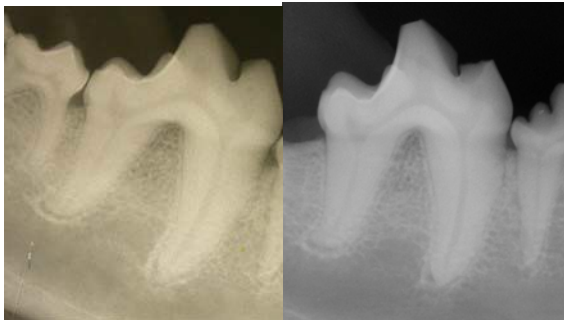
There is a definite increase in the width of the periodontal ligament space at the apex of both roots. There was also some coronal damage as a potential portal of entry for bacteria into the pulp system and even a pulp stone in the chamber in the mesial cusp of the tooth, but as I assessed all the pieces of this particular puzzle, I decided that the radiographic findings in the apical region were within normal limits and I opted to do neither root canal treatment nor extraction. A year later, the tooth looked like this:

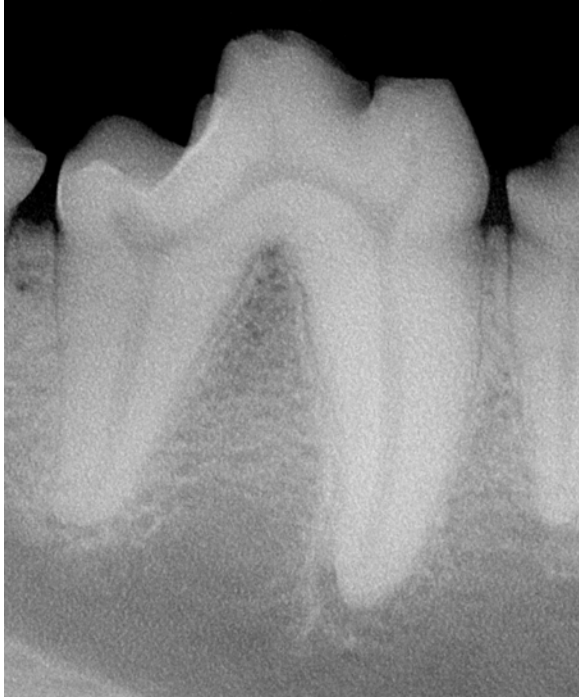

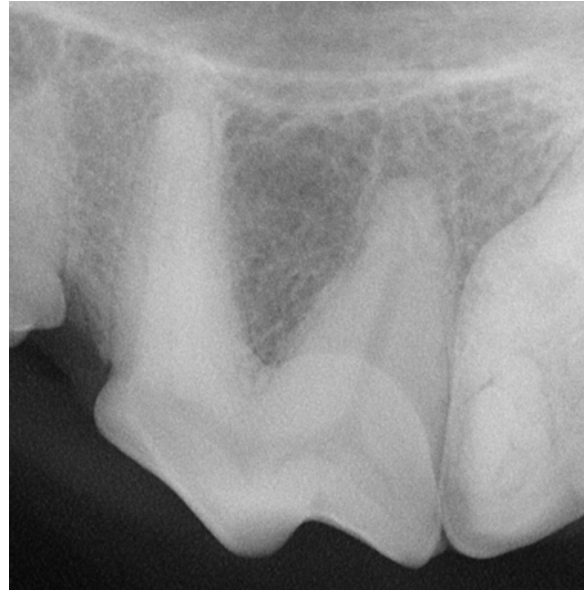Image captured using the ScanX indirect digital system.

The periapical areas look unchanged, suggesting that my initial assessment was correct.

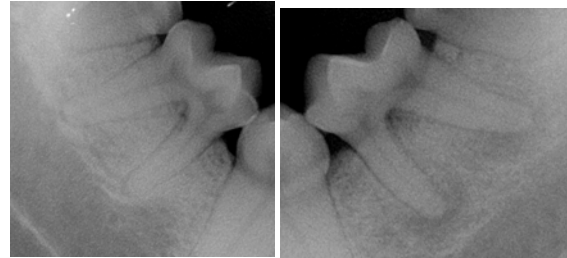
Here are two images of the right mandibular first molar in a different dog. The first is on analog film and the follow-up (a year later) is a ScanX image. Again, the chevron finding is consistent from one year to the next suggesting it is normal for this dog.



The other place I commonly see the chevron sign is at the distal root of the maxillary fourth premolar in large dogs as in this (ScanX) image.



And as a reminder of what a true, endodontically induced chronic periapical periodontitis looks like radiographically, here is a normal right mandibular second molar in a large dog and its diseased left counterpart (both ScanX images):

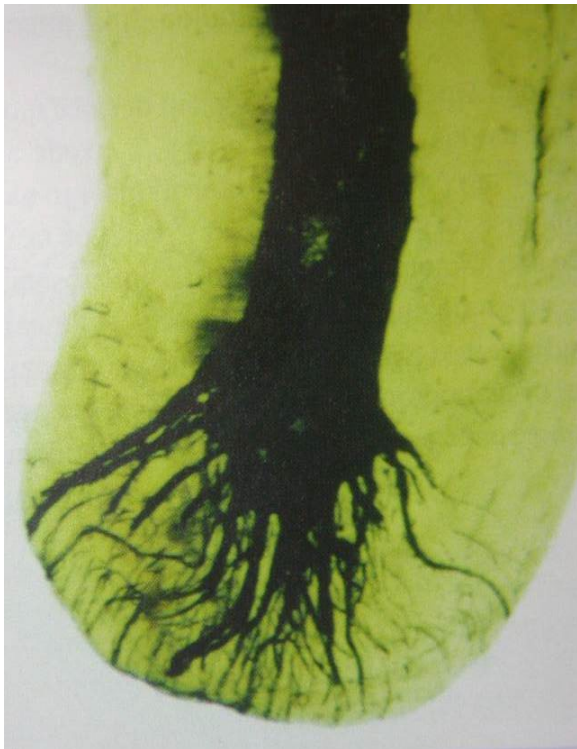

Why did the left second molar develop endodontic disease? Probably occlusal trauma. A good message here is that there does not need to be any coronal damage for a tooth to have endodontic disease and considerable periapical bone demineralization. Therefore, intra-oral dental radiographs **need** to be a part of **every** dental patient's assessment. If you are not taking intra-oral dental radiographs, I can promise you that you are missing pathology and sending many of your patients home with undetected (and un treated) disease.

Back to the chevron sign. To review, we commonly see a widening of the periodontal ligament space and even apparent periapical lucencies associated with perfectly normal teeth. Most commonly this is found in large breed dogs and most commonly it is found at the upper incisor and canine teeth, both roots of the lower first molar tooth and the distal root of the upper

fourth premolar tooth. If one considers the anatomy of the area and the physiology of the tissues, it is really no surprise that this would be the case.

The periodontal ligament serves a number of functions, including shock-absorber for the tooth. The ligament allows some micro-movement of the tooth and allows occlusal forces to be dissipated into the surrounding bone, protecting both tooth and bone from fracture. At the tip of the root, we have the apical delta, comprising many tiny channels. Nerves, blood vessels and lymphatic vessels must leave the protection of bone, traverse the periodontal ligament space and pass through these tiny channels to enter the tooth to become part of the pulp organ.



If the periodontal ligament space is narrow around the apex of the root, when the dog bites down hard on something, the tooth may be intruded into the socket sufficiently to crush the vessels and nerves between the root tip and surrounding bone. A thicker periodontal ligament space around the apex will help protect these tiny structures from such trauma. Effectively, the wider periodontal ligament space at the apex of the big teeth in big dogs is just a thicker cushion to protect the communication between the pulp and the rest of the body.

How do you tell if the radiograph you are looking at shows a normal chevron finding or a real endodontic lesion? That is the challenge. Certainly, you need to look at the radiograph closely. Also compare it to a radiograph of the same tooth on the other side of the

head. Transilluminate the tooth as outlined in the article linked at the beginning of this piece. Examine the tooth for signs of damage that might be expected to cause endodontic disease. Put all the pieces of the puzzle together and make a clinical judgment. For teeth you decide are within normal limits, take follow-up radiographs in six to twelve months.