

## Why Antimicrobials are of Such Limited Use in Dentistry

I wrote on this subject in April of 2004 and so you may wish to review that paper ([www.toothvet.ca/PDFfiles/Antibiotics.pdf](http://www.toothvet.ca/PDFfiles/Antibiotics.pdf)). The following piece is an expanded version of a subtitle within another paper I published April of '09 ([www.toothvet.ca/PDFfiles/Dental\\_Truths.pdf](http://www.toothvet.ca/PDFfiles/Dental_Truths.pdf)) which may also be worth review. Finally, there is a position statement by the American Veterinary Dental College at [www.avdc.org/?q=node/25](http://www.avdc.org/?q=node/25).

Time and again we see histories in which evidence of dental disease has been detected and the first course of action was to prescribe antibiotics or an antiseptic oral rinse. This is putting the cart before the horse (and it is the wrong cart for this horse). Before prescribing any treatment, the first step should be a detailed examination to arrive at an accurate assessment of the condition.

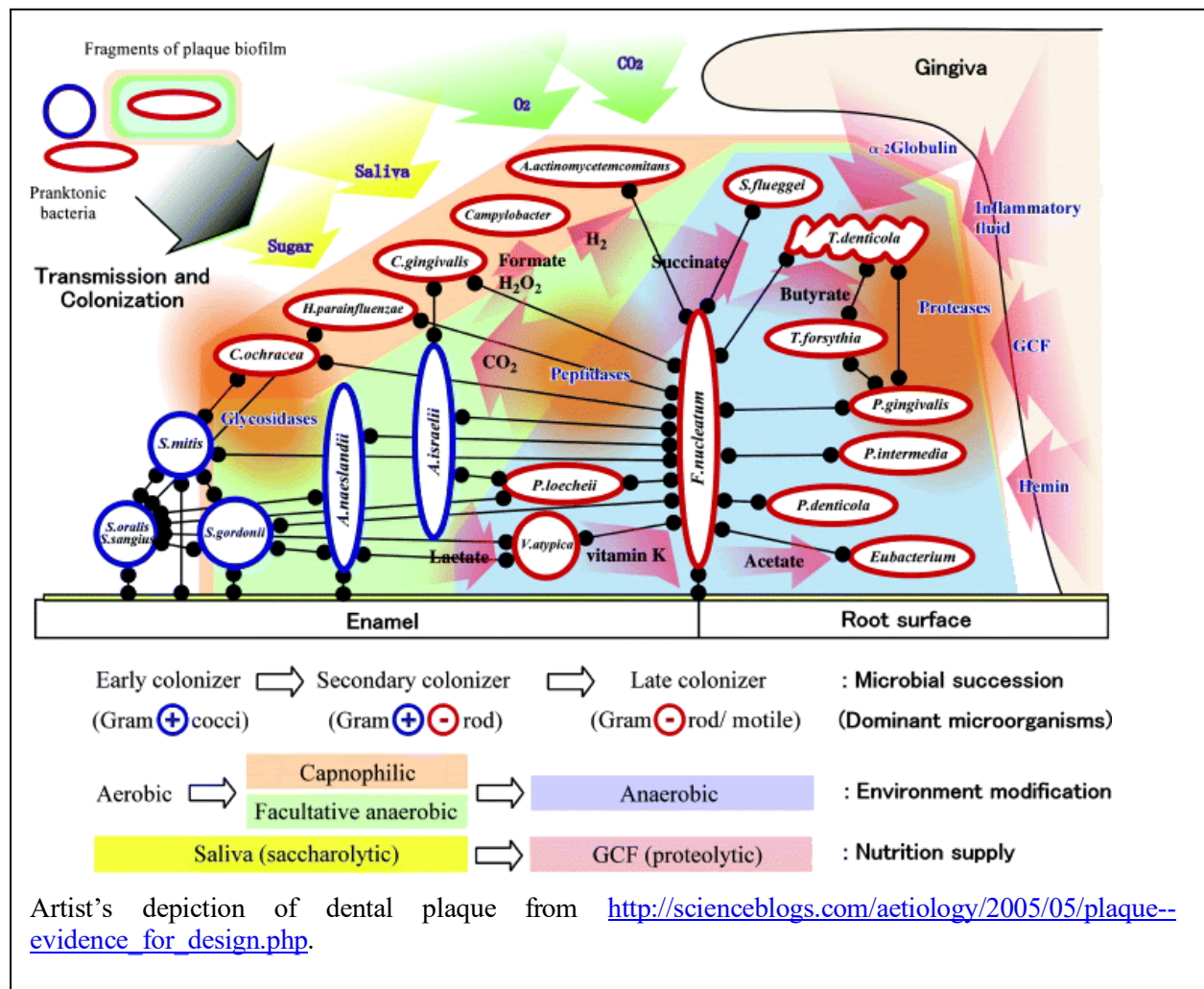
While periodontal disease and gingivitis are the result of the actions of pathogenic bacteria (and the animal's response to them), this is not an infection that can be managed with antibiotics or antiseptic agents. The bacteria that are involved in gingivitis and periodontitis live in a structure known as dental plaque. Plaque is a biofilm which is to say it is a complex structure/society composed of hundreds of species of micro-organism all living within a protective slime that they produce and excrete.

For more on the structure and biology of dental plaque, here are a few pages I found with a quick Google® search:

<http://www.dentistry.leeds.ac.uk/OROFACE/PAGES/micro/micro2.html>

<http://www.dent.ucla.edu/pic/members/microbio/mdphome.html>

Both of those web pages are discussing plaque in human mouths and so there are some differences



in the specifics of the bacteria found there compared to what is found in a dog or cat mouth. Regardless, the principles of plaque development and biology/structure do cross species.

The biofilm resides on the surface of the hard dental structures (crowns and roots of the teeth) and within the pores of any mineral deposits (calculus aka tartar) on these surfaces. There is no blood flow that reaches the biofilm. The soft surfaces of the body (skin, mucosa) constantly slough and replace their superficial layer and thus shed the bacteria that have colonized those surfaces. Enamel and cementum (the superficial tissues of the tooth) do not shed and so once bacteria adhere to these surfaces, they are there until they are removed mechanically. Therefore giving systemic antibiotics, even if they had a spectrum that would target the vast variety of bacteria in the biofilm will not get where the bacteria are living and so will have little effect on them. Systemic antibiotics may help reduce the bacteria count in the surrounding soft tissues and so may make them look better for a time but they will have insufficient effect on the source of the problem.

Some antibiotics can be found in relatively high concentration in saliva but even when we can get the antibiotics to the surface of the biofilm, its structure and ecology affords many protections to the bacteria within. Bacteria in a biofilm are reported to be up to 1500 times more resistant to antimicrobial agents than bacteria in a monoculture. A good review of this can be found at:

[http://books.google.ca/books?id=MbtCOHwAiIQC&pg=PA57&lpg=PA56&ots=X5o2l\\_Vfx8&dq=bacterial+resistance+in+biofilm#PPA56,M1](http://books.google.ca/books?id=MbtCOHwAiIQC&pg=PA57&lpg=PA56&ots=X5o2l_Vfx8&dq=bacterial+resistance+in+biofilm#PPA56,M1).

This book discusses biofilms as they occur in a number of environments including industrial installations as well as on medical implants (catheters, prosthetic joints, heart valves...). Regardless of the location, the principles apply – bacteria in an undisturbed biofilm are very hard to kill.

Another item we often see in histories provided to us is culture and sensitivity testing. In most cases of dental infection (periodontal disease, endodontic disease, chronic stomatitis/mucositis), this is going to be of no

value. Over the years, microbiologists have been able to culture and identify roughly 300 species of microorganism from periodontal pockets. Newer techniques (DNA probing, etcetera) have found that there are 1400 or more species residing in these micro-environments. The discrepancy is because the majority of organisms living in periodontal and endodontic lesions have such fastidious growth requirements that they will only propagate in the complex micro-environment of mature dental plaque. Also, it has been determined that bacteria living in a biofilm, while genetically identical to their planktonic counterparts, have a completely unique biology and physiology. So, doing a culture of an oral infection will tell you which few organisms (of the hundreds present) grow well under specific laboratory conditions and the sensitivity testing will tell which drugs they are sensitive to in planktonic mono-culture. This is probably going to be of no clinical relevance to your patient who is dealing with biofilm *in vivo*.

As well as antibiotics, many people will try antiseptic rinses of one sort or another. While some oral antiseptic can be a useful tool as part of an oral care program none are really of much value as a simple rinse. When we (human patients) use an oral antiseptic, we are instructed to swish/rinse/gargle for 30 to 60 seconds as contact time is important for the agent to have any effect. Dogs and cats do not swish and gargle – they swallow right away and so contact time is severely limited. Also, when we (human patients) use a rinse or mouthwash, we combine this with mechanical plaque removal in the form of flossing and brushing. Simply rinsing with a mouth wash may make the breath less offensive, but there is no real therapeutic effect.

With most endodontic disease, the pulp chamber of the tooth is filled with necrotic pulp debris and bacteria. The bacteria and their toxins ooze out through the tip of the root to cause infection in the tissues around the root tip (periapical periodontitis), but since there is no live tissue inside the tooth, systemic antibiotic do not get into the pulp chamber and so again, can have no effect on the source of the infection.

When a tooth is fractured and the pulp chamber exposed to oral bacteria the tooth effectively

becomes a hollow tube embedded in bone into which the animal is spitting on a constant basis. If you had a surgical-grade stainless steel tube embedded through your thigh into your femur and you spat into it several times a day, would antibiotics be of any value in managing the osteomyelitis that would develop? No, so treatment would depend on removing the portal of entry for the bacteria. You would either remove the steel tube (extraction) or sterilize its interior and seal the opening (root canal treatment).

When a patient is diagnosed as having dental disease, the first step is to get an accurate assessment of that condition. This involves general anesthesia to allow for a complete and detailed clinical examination with a whole-mouth radiographic survey. Once a diagnosis has been established, an appropriate treatment plan can be developed, in consultation with the owner. This is the basis of the COHAT (comprehensive oral health assessment and treatment).

Post-operatively it may be appropriate to dispense some antibiotics or an oral rinse for the short term, but in most cases, once the source of the infection has been removed through effective oral surgery, the body takes care of the rest with no pharmaceutical assistance. The potential benefits of post-operative medications and rinses must be balanced against the potential for the owners to tear open any oral surgical sites as they wrestle with their pet to get the product into the mouth. My preference is for the owners to take a hands-off approach to the mouth for two weeks post-operatively. Therefore, any medications (analgesics for instance) must be taken voluntarily by the patient, hidden in food or treats. The fewer medications we send home, the more likely it is that the patient will actually get them. If the patient is only going to get one medication, I would choose an analgesic over an antibiotic.

There are times when antibiotics can be of some benefit in the treatment plan, but always as a part of a grander scheme, never as a monotherapy.

If you have a compromised patient such as a geriatric diabetic or a cat with FIV, then a pre-induction dose of ampicillin or clindamycin is

warranted. If clinical and/or radiographic findings indicate that there is osteomyelitis that has not been removed surgically or if there is an area of periapical pathology affecting a tooth that has just had root canal therapy, then a course of antibiotics is justified (I typically use clindamycin 1 mg/kg BID for 10 days).

If an animal presents with an acute facial cellulitis (infra-orbital swelling) and it simply is not possible to get the animal to surgery that day or the next, then starting the patient on antibiotics pre-surgically is fine but there is a real danger with doing this. Often, the swelling will come down within a day or two, the patient will be more comfortable and the client may be deluded into thinking that the problem has resolved. They may then call to cancel the surgery. However, the source of the problem is still in place and once the antibiotics are finished, the problem will reoccur. It may take a few weeks for the facial swelling to come back, but you can be certain it will because nothing has been done to address the source. If you find yourself in a position of having to provide some temporary symptomatic relief until you can get the patient to surgery, make sure that the owners know that this is all it is – temporary, symptomatic relief. Regardless of how well the patient is in a day or two the COHAT is still needed to find and remove the source of the infection.